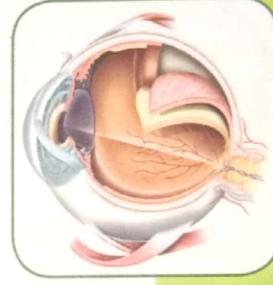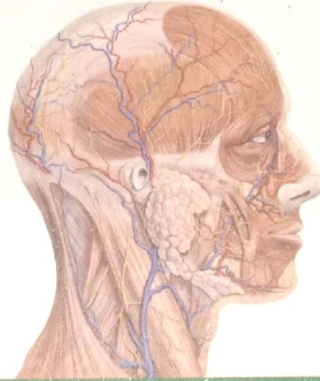



सम्पूर्ण संकलित शालाक्यतंत्र विज्ञान

Comprehensive Compendium of Supraclavicular Disorders in Ayurveda

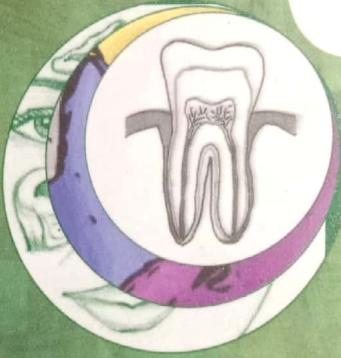नेत्र रोग
नासा रोग
शिरो रोग

कर्ण रोग
मुख रोग
नस्य कर्म



Ophthalmology
Rhinology
Dentistry

Laryngology
Headache
Otology



DR. ATUL BHARDWAJ

HIGH POINTS OF THE BOOK

- CCIM Recommended Curriculum Based Textbook
- Then and There comparison with Modern Counterpart
- Quick Review for PG Preparation
- Inclusion of Different Commentaries at Relevant Places
- Tabular and Point Wise Presentation

Contents

<i>Dedication</i>	iii	Testing intraocular pressure (IOP)	49
<i>Acknowledgement</i>	v	Testing visual field	49
<i>Preface</i>	vii	External examination of eye	50
शालाक्य तंत्र का इतिहास	1	Examination of extraocular movements	51
शालाक्य तंत्र की व्युत्पत्ति	3	Strabismus	51
शालाक्य तंत्र की परिभाषा	3	Amblyopia	52
नेत्र रोग प्रकरण	9	Examination of conjunctiva	53
सुश्रुतानुसार नेत्ररोग वर्णित अध्याय	11	Examination of sclera and episclera	53
अष्टांगहृदय अनुसार नेत्ररोग वर्णित अध्याय	11	Examination of uveal tissue	54
नेत्र रोग वर्णन	12	Examination of cornea	54
नेत्ररोग विभाजन एवं संख्या निरूपण	12	Examination of pupil	54
चिकित्सिय विभाजन	12	Examination of anterior chamber	54
आश्रयानुसार नामकरण	13	Ophthalmoscopy/ fundoscopy	55
वर्त्मगत रोग	14	Clinical examination of lacrimal apparatus	55
शुक्लगत रोग	16	Introduction of tear film	55
कृष्णगत नेत्ररोग	17	Physiology of vision	57
सर्वगत नेत्ररोग	18	Central projection	58
दृष्टिगत रोग	19	Basic sense of the visual pathway	58
चिकित्सा अनुसार विभाजन	25	संधिगत रोग प्रकरण	59
सुश्रुतानुसार नेत्र रोग चिकित्सा का निर्देश	27	पूयालस	59
नेत्र रचना शरीर	28	Dacryocystitis	59
दृष्टि विमर्श	28	उपनाह	62
मण्डल, सन्धि व पटल विमर्श	29	Mucocele and pyocoele of the lacrimal sac	63
नेत्र निर्माण सहायक अवयव	30	नेत्रस्राव/ नेत्रनाड़ी	63
नेत्ररोग सामान्य निदान/ हेतु	30	पर्वणी	64
नेत्र रोग सम्प्राप्ति	30	Benign conjunctival tumors	65
नेत्र रोग पूर्वरूप	30	अलजी	66
नेत्र रोग सामान्य चिकित्सा	31	Conjunctival intraepithelial neoplasia	66
Anatomy of the eyeball	32	कृमिग्रन्थि	67
Orbital cavity	32	Blepharitis	68
Three different layers of the eyeball	33	वर्त्मगत रोग	70
Anatomy of ocular Adenexa	34	उत्संगिनी	70
Anatomy of conjunctiva	36	Chalazion	72
Anatomy of sclera	37	कुम्भीका (सन्निपातिक, लेख्य)	73
Anatomy of cornea	38	पोथकी	73
Anatomy of Anterior chamber	39	Trachoma	74
Anatomy of uveal tract	40	वर्त्मशर्करा/सिकतावर्त्म (अ.ह्.)	77
Anatomy of lens	42	Conjunctival Concretions	78
Anatomy of vitreous	43	अर्शोवर्त्म	78
Anatomy of retina	43	Lid Papilloma	79
Vascular Anatomy of eye (Artery)	44	शुष्कार्श	80
Vascular Anatomy of eye (vein)	44	Lid condyloma	80
Examination of the eye	44	अञ्जननामिका/अञ्जनदूषिका (रक्तजभेद्य)	80
Testing visual acuity	44	External Hordeolum or Sty	81
Refractive errors	45	बहलवर्त्म	82
Myopia/short sightedness	46	Giant Papillary Conjunctivitis	82
Hypermetropia/ Hyperopia / farsightedness/	46	वर्त्मबन्ध/ वर्त्मावबन्ध	83
long sightedness	46	Atopic Dermatitis of Lid	83
Astigmatism	47	क्लिष्टवर्त्म	84
Anomaly of Accommodation (presbyopia)	48	Angioneurotic edema /Angioedema of lids	84

पित्तोक्लिलष्ट रोग	84	अव्रणशुक (सुश्रुतानुसार) / शुद्धशुक (वाग्भट्टानुसार)	139
उत्तिक्लिलष्ट रोग	85	Corneal opacities	140
श्लिलष्ट वर्त्म	85	अक्षिपाकात्यय / पाकात्यय शुक (वाग्भट्ट)	142
वर्त्मकर्म	86	Hypopyon ulcer	144
Mucopurulent conjunctivitis/ Acute bacterial conjunctivitis	86	अजकाजात / अजका (वाग्भट्ट)	145
श्याव वर्त्म	87	Anterior staphyloma	146
Periorbital ecchymosis	87	सिराज शुक (वाग्भट्ट वर्णित)	147
क्लिन्नवर्त्म / प्रक्लिन्नवर्त्म	88	सर्वगत रोग प्रकरण	160
Simple Allergic Conjunctivitis	88	अभिष्यन्द Conjunctivitis	160
अक्लिन्न वर्त्म / अपरिक्लिन्न वर्त्म	89	Classification of conjunctivitis	161
Chronic bacterial conjunctivitis	90	Allergic conjunctivitis	162
वातहत वर्त्म	91	Bacterial conjunctivitis	164
Lagophthalmos	91	Glaucoma अधिमन्ध	165
वर्त्मबुर्द	92	Classification of glaucoma	
Benign growth of the lid	93	Angle closure glaucoma (ACG)/ closed Angle glaucoma	169
निमेष	94	Management of glaucoma	172
Blepharospasm	94	सशोफ अक्षिपाक / अशोफ अक्षिपाक	174
शोणितार्श	95	हताधिमन्ध	177
Cutaneous malignancies of the Lid, Basal Cell carcinoma (BCC) and Squamous Cell Carcinoma (SCC)	96	Pthisis bulbi	178
लगण	98	वातपर्याय	179
बिस वर्त्म	98	Referred eye pain	180
Internal hordeolum	99	अन्यतोवात	180
पक्ष्मकोप / पक्ष्मोपरोध (वाग्भट्ट)	100	शुष्काक्षिपाक	181
Trichiasis	101	Dry eye syndrome (DES) / Dry eye disease/ Keratoconjunctivitis Sicca (KCS) / Keratitis Sicca/Sicca syndrome	182
Entropion	103	अम्लाध्युषित (सुश्रुत) / अम्लोषित (वाग्भट्ट)	185
पक्ष्मशात	104	Acute uveitis	186
कुक्कूणक	105	सिरोत्पात	188
Ophthalmia neonatorum (ON) / Conjunctivitis of the newborn	107	Endophthalmitis	189
शुक्लगत रोग	110	सिराप्रहर्ष / सिराहर्ष	191
Pterygium	113	Panophthalmitis	191
शुक्तिका (पित्तज, अशस्रकृत)	115	नेत्र रोगो मे सामान्य कर्म / पथ्यअपथ्य विचार	193
Conjunctival xerosis	116	दृष्टि रोग प्रकरण	195
अर्जुन	117	तिमिर / काच / लिंगनाश प्रकरण	195
Subconjunctival hemorrhage (SCH)	117	रागप्राप्त लिंगनाश (काच) का दोषानुसार वर्णन	201
पिष्टक (कफज / अशस्रकृत औषधसाध्य)	118	तिमिर, काच एव लिंगनाश एक विवेचन	203
Bitot's spot	119	तिमिर / काच / लिंगनाश चिकित्सा प्रकरण	205
सिराजाल	121	सुश्रुतानुसार प्रत्यजन वर्णन	207
सिरापिडिका	121	तिमिर चिकित्सा योग	208
Scleritis - सिराजाल	122	कफज लिंगनाश चिकित्सा / लिंगनाश शस्त्रकर्म	209
Episcleritis - सिरापिडिका	124	Cataract	216
बलास ग्रथित (कफज / अशस्रकृत औषध साध्य)	125	Classification of cataract	216
Conjunctival inclusion cyst	126	Symptoms of cataract	217
कृष्णगत रोग	127	Signs of cataract	218
सव्रण शुक / क्षतजशुक (वाग्भट्ट)	127	Indications of cataract surgery	219
Ulcerative keratitis/Corneal ulcer	130	Steps of operative procedure	221
Definition	130	Complications of cataract surgery	223
Classification of ulcerative keratitis	130	संसर्ग तिमिर या परिम्लायि रोग	224
Bacterial keratitis	131	Vitreous hemorrhage	224
Viral keratitis	134	पित्तविदग्ध दृष्टि	226
Fungal /mycotic corneal ulcer	137	Day blindness/Hemeralopia	227
Acanthamoeba/protozoal keratitis	138	श्लेष्मविदग्ध दृष्टि / नक्तान्ध / रात्रान्ध / दोषान्ध	227
		Night blindness/ Nyctalopia/	

Impaired dark adaptation	228	Tinnitus	314
उष्णविदग्धा दृष्टि(वाग्भट्टानुसार वर्णित व्याधि)	229	कर्णश्वेद	318
धूमदर्शी/धूमर (वाग्भट्ट)	229	कर्ण बाधिय	319
Blurred vision due to macular pathologies	230	Deafness/Hearing loss	321
ह्रस्वजाड्य/ह्रस्वजा (वाग्भट्ट)	232	Noise induced hearing loss (NIHL)/	
Micropsia	232	Occupational hearing loss/Acoustic trauma	323
नकुलान्ध्य सन्निपातज/असाध्य	233	Tympanoplasty	326
Retinitis pigmentosa (RP)	233	कर्णद्राव	328
गम्भीरिका/गम्भीरा दृष्टि (वाग्भट्टानुसार)	235	Chronic otitis media (COM) or	
भेषज्य रत्नावली मे नेत्र रोग चिकित्सा	235	chronic suppurative otitis media	329
सुश्रुत/वाग्भट्ट (नेत्रप्रकरण) मे वर्णित कुछ		CSF Otorrhea	333
प्रमुख योग व इनके रोगाधिकार	242	कर्णकण्डू व कर्णगूध (कर्णवर्ध)	335
घरकानुसार वर्णित नेत्ररोग चिकित्सा	243	चिकित्सा	335
बाह्य नेत्र रोग	245	Fungal otitis externa (Otomycosis) कर्णकण्डू	336
Optic neuritis सनिमित्त लिगनाश	245	Ear wax कर्णगूध (कर्णवर्ध)	337
Decreased vision due to retinal		कर्णप्रतिनाह	337
pathologies - अनिमित्त लिगनाश	247	चिकित्सा	338
Hypertensive retinopathy	250	Tympanic membrane perforation	338
Central serous retinopathy (CSR)	251	कृमि कर्ण	340
Eales disease	253	Foreign body of the ear	341
Optic atrophy	254	कर्णविद्रधि	342
Community ophthalmology	257	Localized otitis externa (Furunculosis)	345
National Programme for Control of		कर्णपाक	345
Blindness (NPCB) in India	257	Diffused otitis externa	346
Vision 2020 The Right to Sight	258	कर्णपूति/पूतिकर्ण	347
Globally commenced mechanism to		Chronic suppurative otitis media (CSOM)	
tackle blindness	259	with cholesteatoma	348
क्रियाकल्प प्रकरण	261	कर्ण अर्श, शोफ, अबुर्द	350
क्रियाकल्प	263	कर्ण अर्श Aural Polyps	352
तर्पण (नेत्रपुष्टिकारक एवं रोग निवारक)	264	शोफ प्रकरण	353
तर्पण योग्य	264	कर्णशोफ Perichondritis and chondritis of pinna	355
विडालक	277	अर्बुद प्रकरण	356
अत्रजन	277	कर्ण अर्बुद Tumors of the ear	357
अजन शलाका	281	कर्णशष्कुली रोगकुचिकर्णक, कर्णपिप्पली, विदारिका	360
कर्ण रोग	283	कर्ण पाली के रोग	361
कर्ण रोग	285	पालीशोष	362
सख्या निरूपण	285	तन्त्रिका	363
सदर्भ अध्याय	285	परिपोट	363
विभिन्न संहिताओं में कर्ण रोग नामकरण व सख्या निरूपण	285	उत्पात	364
संस्थान निरूपण	286	उन्मन्ध/गल्लिर	365
कर्णरोगों के सामान्य व निदान सम्प्राप्ति	288	दुःखवर्धन	365
चरकोक्त कर्ण रोग विवेचन	289	कर्णपाली रोगों की सामान्य चिकित्सा	366
Anatomy of the ear	291	कर्णरोगों में विभिन्न आचार्यों द्वारा वर्णित कुछ विशिष्ट योग	367
External ear	291	भेषज्यरत्नावली मे कर्णरोग चिकित्सा प्रकरण	369
Tympanic membrane (TM)	292	कर्ण व्यधबन्ध विधिभध्याय	371
Middle ear or Tympanic Cavity	292	कर्ण विच्छिन्ता का कारण	371
Internal ear (Labyrinthine cavity)	294	पञ्चदश कर्ण बन्धनाकृतय	371
Physiology of Hearing	297	नामकरण का आधार/वर्गीकरण का आधार	371
Examination of the ear	298	साध्य कर्णबन्धन	372
Assessment of hearing	301	असाध्य कर्णबन्धन	372
कर्णरोगों की सामान्य चिकित्सा	308	नासा विच्छिन्ता के कारण	374
कर्णपूरण	308	नासा सधान	374
कर्णशूल	309	ओष्ठ सधान	374
Otalgia/Pain in the ear	312	Otoplasty/Cosmetic correction of the pinna	375
कर्णनाद	313	The standard otoplasty surgical steps	376

नासा रोग प्रकरण	377	नासाशोथ या शोफ	450
संदर्भ अध्याय	379	नासा अर्श Nasal polyp	452
नासा रोग संख्या निरूपण	379	Overview	
विभिन्न संहिताओं के नाम निरूपण	379	नासा अर्बुद - Tumours of nasal cavity and paranasal sinuses (Sinonasal neoplasms)	454
Anatomy of the nasal cavity	384	Overview	454
Examination of external nose	390	विभिन्न आचार्यों द्वारा नासा रोग प्रकरण में वर्णित	
Anterior rhinoscopy	391	कुछ महत्वपूर्ण योग	457
Endoscopic examination	391	नासा रोग प्रकरण में भैषज्य रत्नावली में वर्णित	
Radiological examination	391	कुछ महत्वपूर्ण योग	459
नासारोग सामान्य निदान व सम्प्राप्ति/		मुख रोग प्रकरण	461
प्रतिश्याय सामान्य निदान व सम्प्राप्ति	392	संदर्भ अध्याय	463
प्रतिश्याय	393	मुख रोग संख्या निरूपण	463
व्युत्पत्ति	393	विभिन्न आचार्यों द्वारा वर्णित मुखरोग अधिष्ठान नामकरण	464
प्रतिश्याय हेतु	393	ओष्ठगत रोग	464
प्रतिश्याय सामान्य चिकित्सा सिद्धान्त	395	दंतमूलगत रोग	465
प्रतिश्याय सामान्य चिकित्सा	397	दंतगत रोग	466
दोषज भेद से प्रतिश्याय वर्णन	398	जिह्वागत रोग	466
वातज प्रतिश्याय	398	तालुगत रोग	467
Allergic rhinitis (AR)	401	कंठगत रोग / गलगत रोग	467
पित्तज प्रतिश्याय	404	सर्वसर रोग	468
Acute viral rhinitis/common cold/coryza	406	साध्यतासाध्यता विवेचन	469
कफज प्रतिश्याय	407	Anatomy & clinical examination of the oral cavity	470
Rhinitis caseosa	409	Anatomy & clinical examination of the pharynx	475
सन्निपातज या त्रिदोषज प्रतिश्याय	410	Anatomy & clinical examination of the larynx	478
रक्तज प्रतिश्याय	411	Examination of head and neck lymph nodes	483
Atrophic Rhinitis/Ozaena	412	मुख रोग सामान्य सम्प्राप्ति / कारण / सामान्य निदान	485
दुष्टप्रतिश्याय या दुष्ट पीनस	413	चरक द्वारा वर्णित मुख रोग	485
Rhinosinusitis (RS)	417	चरकोक्त मुख रोग चिकित्सा	486
Medical management of sinus diseases	419	चरकोक्त मुखरोग चिकित्सा में कुछ प्रमुख योग	487
आम व पक्व प्रतिश्याय (पीनस) विश्लेषण	421	विभिन्न आचार्यानुसार समस्त मुखरोग निरूपण	488
आम व पक्व पीनस में चिकित्सा सूत्र	423	ओष्ठगत रोग	488
अपीनस	425	वातज ओष्ठरोग / ओष्ठ प्रकोप / ओष्ठकोप	488
अपीनस चिकित्सा	426	Angular cheilitis	489
Chronic rhinitis	427	पित्तज ओष्ठ रोग	489
पूतिनस्य या पूतिनासा	428	Herpes labialis/Viral Eruptions of the lip	490
Pathological CSF rhinorrhoea	430	कफज ओष्ठ रोग	491
नासापाक घ्राणपाक (चरक)	431	Angioneurotic edema /angioedema of lips	492
Acute vestibulitis	432	सन्निपातज ओष्ठ रोग	492
नासागत रक्तपित्त / शोणितपित्त	432	Carcinoma of the lip	493
Epistaxis	434	रक्तज ओष्ठरोग / ओष्ठ अर्बुद	494
Classification of epistaxis	435	Granulomatous lip	495
पूयशोणित या पूयरक्त या पूयाञ्च	437	मांसज ओष्ठ प्रकोप	495
क्षवधु या भृशक्षव (वाग्भट्ट)	438	Ulcerative squamous cell carcinoma of the lip	496
Non allergic non infective rhinitis (NANIR)	440	मेदोज ओष्ठरोग	496
भ्रशधु	441	Mucus retention cyst of lip/lip mucocele	497
Nasopharyngitis	441	अभिघातज क्षतज ओष्ठरोग	497
नासादीप्त	442	Trauma of Lip	498
नासाप्रतिनाह या नासानाह (वाग्भट्ट)	443	जलार्बुद (अष्टांग हृदय / अष्टांग संग्रह)	498
Rhinoscleroma	444	गण्डगत रोग (वाग्भट्ट वैशिष्ट्य)	498
Deviated nasal septum (DNS)	444	दंतमूलगत रोग	499
नासाद्राव या नासापरिद्राव	446	शीताद	499
Vasomotor rhinitis (VMR)/Non infective		Periodontitis	500
Non allergic rhinitis/Intrinsic rhinitis	447	दंतपुण्डक	502
नासाशोथ या नासापरिशोथ (चरक)	448	दन्तवैष्टक	503
Rhinitis Sicca	449		

Aggressive periodontitis	504	तुण्डिकेरी	555
शौषिर/सुषिर	505	Tonsillitis	558
Acute gingivitis	506	कच्छप	559
महाशौषिर/महासुषिर	507	Torus palatines	559
Necrotizing periodontal disease	508	अघुष	560
परिदर	508	Lingual Tonsillitis	561
Chronic Gingivitis	509	तालु अर्बुद	561
उपकुश	510	Carcinoma of the hard palate	563
Pyorrhoea alveolaris	511	माससंघात	563
दंत वैदर्भ विदर्भ (वाग्मट्ट)	512	Papilloma of the oral cavity	563
Gingival recession	513	तालुपुप्पुट	564
वर्धन/खल्लिवर्धन	514	तालुशोष	565
Extradentition/Hyperdontia/Supernumerary teeth	515	Oronasal/Oroantral Fistula	565
अधिमास	516	तालुपाक	566
Pericoronitis	516	Mucous Membrane Pemphigoid (MMP)	566
दंत नाडी (पाच प्रकार)	517	तालुविद्रधि (चरक वैशिष्ट्य)	566
Periapical abscess	519	तालुपिटिका (वाग्मट्ट विशेष)	567
दन्तविद्रधि	520	कठ रोग/गल रोग प्रकरण	567
दन्त रोग प्रकरण	521	पंचरोहिणी	567
दालन शीतदन्त (वाग्मट्ट)	521	1 वातज रोहिणी	567
Dental Erosion with pulp exposure	522	2 पित्तज रोहिणी	568
कृमिदन्त	522	3 कफज रोहिणी	568
Dental caries	524	4 त्रिदोष रोहिणी	568
दन्त हर्ष	526	5 रक्तज रोहिणी	568
Pulpitis/pulpal pain	527	चरकानुसार रोहिणी वर्णन	569
भजनक दंतभेद (वाग्मट्ट)	527	Pharyngitis	571
Osteomyelitis of Maxilla and/or Mandible	528	Diphtheria	573
दन्तशर्करा	530	कण्ठशालूक/शालूक	574
Dental Calculus	531	Adenoids/ Nasopharyngeal tonsils	574
कपालिका	532	अधिजिह्वा	575
Teeth attrition and abrasion/erosion	533	वलय	576
श्यावदन्तक/श्यावदन्त	533	Carcinoma of Larynx/laryngeal malignancies	577
Staining of the Teeth (Tooth discoloration)	534	बलास/बलाश	580
हनुग्रीव	534	एकवृन्द	581
प्रसंगवश सुश्रुतोक्त अर्दित रोग वर्णन	535	Cervical Lymphadenitis	581
प्रसंगवश विभिन्न आचार्यों द्वारा उद्धृत हनुग्रह वर्णन	536	वृन्द	582
Temporo-mandibular Joint (TMJ) Dislocation	537	Neck space infections (NSI)	583
दन्तचाल	538	शतघ्नी	586
दंत रोगों में अपथ्य विवेचन	540	गिलायु	587
दंत आहारण (निर्हरण) संबंधी नियम	540	गलविद्रधि	587
जिह्वा रोग प्रकरण	542	Parapharyngeal abscess	588
जिह्वा त्रिकटक	542	गलीघ	589
वातज जिह्वाकण्ठक Fissured Tongue	543	Acute simple Laryngitis with	
पित्तज कण्ठक Glossitis	544	vocal cord involvement	590
कफज कण्ठक Macroglossia/Tongue hypertrophy	545	स्वरघ्न/स्वरहा (वाग्मट्ट)	591
अलास	545	Vocal cord paralysis (VCP) and immobility	592
Ludwig's angina	546	मासतान	594
उपजिह्विका	547	विदासी	595
उपजिह्विका	548	Retropharyngeal abscess (RPA)	595
Ranula/Sublingual gland retention cyst	548	गलगण्ड	597
अधिजिह्विका	550	गलाबुंद	600
अधिजिह्विका Epiglottitis/Supraglottitis	551	कण्ठ रोगों की सामान्य चिकित्सा	600
तालुगत रोग	553	सर्वसर रोग प्रकरण	601
गलशुण्डिका	553	वातज मुखपाक	601
Elongated uvula	554		

शालाक्य तंत्र का इतिहास

महेश कुमार शर्मा

व्युत्पत्ति-

- शलाका, तस्याः कर्म, तत्प्रधानं तन्त्रं शालाक्यं।
- शलाकया यत्कर्म क्रियते तच्छालाक्यम्।

परिभाषा-

शालाक्यं नामोर्ध्वजत्रुगतानाम् रोगाणां श्रवणनयनवदनघ्राणादिसंश्रितानाम् व्याधिनामुपशमनार्थम् शलाकायन्त्रप्रणिधानार्थं च।। (सु.सू. 1/7/2)

- शालाक्याः कर्म शालाक्यं, तत्प्रधानं तन्त्रमपि शालाक्यम्। -डल्हण (सु.सू. 1/7)
- शालाक्यमित्यादि। जत्रु ग्रीवामूलम्, अग्न्ये वक्षोऽससन्धिमाहुः। वदनमत्र मुखकुहरमाहुः। घ्राणादिसंश्रितानामित्यत्र आदि शब्दाच्छिरः कपालादिसंश्रितानाम्।। डल्हण (सु.सू. 1/7)

An oculist who uses sharp instruments, employment of pointed instruments as a branch of surgery. The science of using sharp instruments for diseases of the eye etc.

(M.Monier - Williams Dictionary)

शालाक्य तन्त्र का इतिहास:-

चिकित्सा शास्त्र शाश्वत एवं अनादि है। यह विभिन्न रूपों में सृष्टि की रचना के साथ ही विद्यमान रहकर उसकी रक्षा करता रहा है। भारतीय वांगमय में ज्ञान के प्राचीनतम स्रोत वेदों में भी चिकित्सा संबंधी सूत्र विद्यमान हैं। चिकित्सा का विभाजन विभिन्न अंगों में तो आगे चलकर संहिता काल में प्रत्यक्ष होता है परन्तु सुश्रुत संहिता में संदर्भ के आधार पर अष्टांग विभाजन कर ब्रह्मा ने शालाक्य तंत्र को स्वतंत्र अस्तित्व प्रदान किया।

शालाक्य तन्त्र के उपदेष्टा के रूप में विदेह अधिपति निमि का नाम आता है।

शालाक्यतन्त्रभिहिता विदेहाधिपकीर्तिताः।। (सु. उ. 1/5)

ब्रह्मा द्वारा विभाजित अष्टांग आयुर्वेद में शालाक्य तन्त्र अपना द्वितीय स्थान रखता है।

इह खलु नराणां भूयोऽष्टधा प्रणीतवान्।। (सु. उ. 1/6)

शालाक्य तन्त्र के विशारद को शालाकी कहा जाता था। शालाक्य तन्त्र का सम्बन्ध जत्रुकास्थि के ऊपर के अंग अर्थात् कर्ण, मुख, नासा, नेत्र एवं शिर से होता था। शिर की उपयोगिता के विषय में चरक ने सभी इन्द्रियों एवं प्राणों का आश्रय बता कर सिद्ध किया है।

प्राणाः प्राणमृतां यत्राश्रिताः सर्वेन्द्रियाणि च।

यदुत्तमांगंगानां शिरस्तदभिधीयते। (च. सू. 17/3)

किसी भी विषय का ऐतिहासिक अनुशीलन उसके विकास एवं अनुसंधान के मार्ग को प्रशस्त करता है। शालाक्य तन्त्र के विषय में भी हम काल विभाग के अनुसार चार खण्डों में उसका अध्ययन कर सकते हैं।

काल विभाग:-

1. वैदिक काल (<600 B.C)
2. प्राचीन काल (600 BC - 700 AD)
3. मध्य काल (800 AD - 1500 AD)
4. आधुनिक काल (> 1600 AD)

1. वैदिक काल:-

वैदिक काल 5000 ई पूर्व से 600 ई पूर्व तक माना जाता है। वैदिक काल में आयुर्वेद का कोई विभाग नहीं था। इस काल में वेदों में चिकित्सा सम्बन्धी सूत्र प्राप्त होते थे। जिनसे वैदिक शास्त्रों में शालाक्य तन्त्र के बीज स्वरूप अंकुर उत्पन्न होकर आगे तन्त्र रूप में विकसित हुए। वेदों में शालाक्य तन्त्र सम्बन्धित संदर्भ-

ऋग्वेद-

वेदों में अश्विनी कुमारों को देवभिषक् का दर्जा प्राप्त था। उनके द्वारा चिकित्सा के चमत्कारों में शालाक्य के कुछ उदाहरण प्राप्त होते हैं।

1. उपासक कण्ठ को चक्षु दिए। (ऋ. 1/118/7)
2. ऋषि परावृक को नेत्र हीनता से नेत्र सम्पन्न किया। (ऋ. 1/112/8)
3. दधीचि ऋषि के शिर का सन्धान किया। (ऋ. 1/119/9)
4. ऋजाश्व के अधेपन को दूर किया। (ऋ. 1/116/16)
5. नृषद पुत्र को कर्ण देकर बधिरता को दूर किया। (ऋ. 1/118/8)
6. नेत्र रोगों की चिकित्सा का ज्ञान। (ऋ. 10/39/3)

यजुर्वेद:-

मन्त्र चिकित्सा से दृष्टि प्राप्ति। - तैत्तिरीय संहिता (2/1/1/1)

अथर्ववेद:-

आज्जन मणि को नेत्रों के लिए हितकर तथा नेत्र रोग नाशक कहा गया। (अथर्ववेद 7/30/1, 7/36/1)

वैदिक काल में अश्विनी कुमारों के अष्टांग विशारद होने के प्रमाणों में शालाक्य सम्बन्धी उदाहरण प्राप्त होते हैं। जो परवर्ति ग्रन्थों में भी प्राप्त हुए। चिकित्सा के अन्य कोई विभाग नहीं थे आगे चलकर अष्टांग विभाजन प्राचीन काल में हुआ जो संहिताओं में स्पष्ट रूप से प्रदर्शित होता है।

जीवक:- (600 BC)

तक्षशिला विश्वविद्यालय से चिकित्सा (शालाक्य तन्त्र) का सात वर्ष अध्ययन एवं अभ्यास करने के पश्चात् अपने चिकित्सा कौशल से विश्व में ख्याति अर्जित करने वाले आचार्य जीवक थे।

“नानीषधिभूत जगति किंचिद वर्तते”

अर्थात् इस जगत में समस्त द्रव्यौषध प्रयुक्त योग्य है। यह प्रसिद्ध वाक्य जीवक का ही है।

चिकित्सा के क्षेत्र में जीवक के कुछ प्रसिद्ध कार्य:-

- o अयोध्या में एक घनाढ्य महिला की 7 वर्ष प्राचीन शिरोवेदना को घृत नस्य दे कर ठीक करना।
- o शिरोवेदना से पीड़ित महिला का कपालभेदन द्वारा रोग मुक्त करना।

जीवक के द्वारा कोई रचित ग्रन्थ प्राप्त नहीं होता है, परन्तु चिकित्सा के क्षेत्र में उनके द्वारा कृत अद्भुत कार्य यत्र तत्र बौद्ध, जैन भिक्षुओं के ग्रन्थों में प्राप्त होते हैं। यह वृत्तान्त प्राचीन काल के शालाक्य तन्त्र के उत्कृष्ट स्वरूप को प्रदर्शित करता है।

2. प्राचीन काल:-

प्राचीन काल का समय उत्तर गुप्त काल 7वीं शती तक माना जाता है। इस काल में मुख्य रूप से संहिता ग्रन्थ अस्तित्व में आए। संहिता ग्रन्थों में प्राप्त शालाक्य तन्त्र के संदर्भ में-

सुश्रुत संहिता-

- उत्तर तन्त्र - 1 से 19 अध्याय - नेत्र चिकित्सा
- उत्तर तन्त्र - 20 से 21 अध्याय - कर्ण चिकित्सा
- उत्तर तन्त्र - 22 से 24 अध्याय - नासा चिकित्सा

उत्तर तन्त्र - 25 से 26 अध्याय - शिरोरोग चिकित्सा

निदान स्थान - 16 अध्याय - मुख रोग चिकित्सा

सुश्रुत संहिता में सुश्रुत द्वारा रचित शालाक्य तन्त्र को निमि तन्त्र से आधार लेकर लिखा है जिनमें नेत्र शरीर, निदान, चिकित्सा कर्मों का विस्तृत विवेचन किया गया है। निमि तन्त्र वस्तुतः प्राप्त नहीं है। परन्तु डल्हण द्वारा यत्र तत्र सदर्भा को उद्धृत किया गया है जो कि निमि तंत्र के अस्तित्व को सिद्ध करता है।

चरक संहिता:-

चरक सूत्र स्थान - 17वां अध्याय

चरक सूत्र स्थान - 18वां अध्याय

निदान स्थान - 7वां अध्याय

निदान स्थान - 8वां अध्याय

चिकित्सा स्थान - 9, 10, 12, 26 अध्याय

सिद्धि स्थान - 9 अध्याय

चरक संहिता मुख्य रूप से काय चिकित्सा प्रधान ग्रन्थ है। इसमें अष्टांग विभाजन सूत्र स्थान के 30वें अध्याय में दिया गया है। शालाक्य तन्त्र का विषय विकीर्ण स्वरूप संहिता से प्राप्त होता है।

अष्टांग संग्रह-

सूत्र स्थान - 29 (नस्य) वां अध्याय

- 30 (धूमपान) वां अध्याय

- 31 (गण्डूषादि) वां अध्याय

- 32 (आश्च्योतन) वां अध्याय

- 33 (तर्पण पुटपाक) वां अध्याय

चिकित्सा स्थान अध्याय-

अध्याय 9 (उन्माद)	अध्याय 10 (अपस्मार)
अध्याय 11 (वर्त्मरोग विज्ञानीय)	अध्याय 12 (वर्त्मरोग प्रतिषेध)
अध्याय 13 (सन्धि सितासितरोग विज्ञानीय)	अध्याय 14 (सन्धि सितासितरोग प्रतिषेध)
अध्याय 15 (दृष्टिरोग विज्ञानीय)	अध्याय 16 (तिमिर प्रतिषेध)
अध्याय 17 (लिंगनाश प्रतिषेध)	अध्याय 18 (सर्वाक्षिरोग विज्ञानीय)
अध्याय 19 (अभिष्यन्द प्रतिषेध)	अध्याय 20 अक्षिपाकपिल्ल प्रतिषेध
अध्याय 21 कर्णरोग विज्ञानीय	अध्याय 22 कर्णरोग प्रतिषेध
अध्याय 23 नासारोग विज्ञानीय	अध्याय 24 नासारोग प्रतिषेध
अध्याय 25 मुखरोग विज्ञानीय	अध्याय 26 मुखरोग प्रतिषेध
अध्याय 27 शिरोरोग विज्ञानीय	अध्याय 28 शिरोरोग प्रतिषेध

अष्टांग हृदय:-

सूत्रस्थान - अध्याय 20 नस्य विधि

अध्याय 22 गण्डूषादि विधि

अध्याय 24 तर्पणपुटपाक विधि

अध्याय 21 धूमपान

अध्याय 23 आश्च्योतांजनविधि

उत्तरतन्त्र -

अध्याय 8 वर्न्मरोग विज्ञानीय

अध्याय 10 सन्धिसितासितरोग विज्ञानीय

अध्याय 12 दृष्टिरोग विज्ञानीय

अध्याय 14 लिंगनाशप्रतिषेध

अध्याय 16 सर्वाक्षिरोग प्रतिषेध

अध्याय 18 कर्णरोग प्रतिषेध

अध्याय 20 नासारोग प्रतिषेध

अध्याय 22 मुखरोग प्रतिषेध

अध्याय 24 शिरोरोग प्रतिषेध

अध्याय 9 वर्न्मरोग प्रतिषेध

अध्याय 11 सन्धिसितासितरोग प्रतिषेध

अध्याय 13 तिमिर प्रतिषेध

अध्याय 15 सर्वाक्षिरोग विज्ञानीय

अध्याय 17 कर्णरोग विज्ञानीय

अध्याय 19 नासारोग विज्ञानीय

अध्याय 21 मुखरोग विज्ञानीय

अध्याय 23 शिरोरोग विज्ञानीय

प्राचीन काल में संहिताओं में शालाक्य तंत्र का विस्तृत वर्णन प्राप्त होता है जो इसकी व्यापकता को प्रदर्शित करता है। चिकित्सा में शालाक्य संबंधित उपक्रमों का विस्तृत वर्णन चारों संहिताओं में उपलब्ध है जो कि शालाक्य तन्त्र के विकसित स्वरूप को प्रदर्शित करता है। सुश्रुत संहिता, अष्टांग संग्रह एवं हृदय में विषय विस्तृत रूप में वर्णित है।

मध्यकाल:-

मध्यकाल 8वीं शती से लेकर 15वीं शती तक माना जाता है। इस काल में भारतीय चिकित्सा के क्षेत्र में नए पड़ाव आए। संहिताओं के अध्ययन को छोड़कर विषय प्रधान अध्ययन प्रारम्भ हुए। इसी काल में निदान, रसशास्त्र आदि छोटे-छोटे ग्रन्थ बनाए गए। शालाक्य तन्त्र की दृष्टि से विशेष ग्रन्थों का निर्माण तो नहीं हुआ यह विषय इन विषय प्रधान ग्रन्थों में सम्मिलित ही पाया गया जो कि समाज में शालाक्य तन्त्र की स्थिति को स्पष्ट करता है। विशिष्ट स्थान प्राप्त नहीं होते हुए भी सम्मिलित रूप में शालाक्य चिकित्सा विद्यमान थी।

माधव निदान (8वीं शती)

1. अध्याय 56 मुखरोग निदानम्
2. अध्याय 57 कर्णरोग निदानम्
3. अध्याय 58 नासारोग निदानम्
4. अध्याय 59 नेत्ररोग निदानम्
5. अध्याय 60 शिरोरोग निदानम्

शार्ङ्गधर संहिता (13वीं शती)

पूर्वखण्ड - अध्याय 7 रोगभेद परिचय, नेत्र, कर्ण, नासा, शिरोगत रोगों का परिचय दिया है।

मध्यखण्ड - औषध कल्पनाएं एवं उनके निर्माण का वर्णन।

उत्तरखण्ड - अध्याय 8 नस्य

अध्याय 9 धूमपान

अध्याय 10 गण्डूष कवल

अध्याय 11 लेप आलेप

अध्याय 13 नेत्र रोग नाशक उपचार

भाव प्रकाश निघण्टु (15-16वीं शती)

मध्यखण्ड - धूमपानादि विधियों का उल्लेख किया है।

उत्तरखण्ड - यत्र तत्र शालाक्य सम्बन्धी विषय विकीर्ण रूप में प्राप्त होता है।

उक्त संदर्भ मध्यकाल में चिकित्सा व्यवस्था में शालाक्य संबंधी रोगों के उपचार एवं औषध कल्पनाओं की विशिष्ट स्थिति के द्योतक हैं। शालाक्य तंत्र के ग्रन्थों एवं शिक्षण को लेकर यह काल गौण रहा है।

आधुनिक काल (16वीं शती से आगे):-

आधुनिक काल में भारत में डच, ग्रीक आदि विदेशी लोगों का आगमन हुआ जो अपने साथ प्रचलित चिकित्सा विधियां लेकर आये थे। आयुर्वेद भी इस काल में मुगल साम्राज्य के आक्रमणों एवं अधिपत्य के कारण क्षीण हो गया था। इस काल में क्रमशः आयुर्वेद का विकास 17वीं शताब्दी के पश्चात् विभिन्न स्थानों पर विकीर्ण रूप में हो रहा था। अन्य चिकित्सा पद्धतियों के प्रभाव से विषय प्रधान अध्ययन प्रचलित होने के कारण शालाक्य तन्त्र विशिष्ट विषय के रूप में स्थापित होकर अध्ययन अध्यापन प्रारम्भ हुआ। वर्तमान समय में शालाक्य तन्त्र के निम्न विभाग हैं-

1. नेत्र चिकित्सा (Ophthalmology)
2. कर्ण-नासा-मुख चिकित्सा (ENT)
3. दन्त चिकित्सा (Dentistry)
4. शिरोरोग चिकित्सा (Head & Neurology)

इस प्रकार हम देखते हैं कि वैदिक परम्परा में शालाक्य तन्त्र आयुर्वेद का एक विशिष्ट अंग था, जो संहिता काल में एक अंग (शालाक्य तन्त्र) के रूप में सभी संहिताओं में वर्णित है। जो इसके महत्व एवं विशिष्टता को प्रदर्शित करता है। मध्यकाल में विषय प्रधान अध्ययन प्रारम्भ हुआ लेकिन शालाक्य तन्त्र को उसमें स्थान नहीं मिला। यद्यपि शालाक्य गत रोगों एवं चिकित्सा उपक्रमों का वर्णन सभी ग्रन्थों में प्राप्त होता रहा। इसका कारण शल्यतन्त्र के प्रति समाज में जैन एवं बौद्ध धर्मों का प्रभाव रहा जिसमें हिंसा का घृणित कार्य के रूप में देखा जाता था।

आधुनिक काल में अन्य चिकित्सा पद्धतियों के प्रभाव में शालाक्य को एक विशिष्ट विषय का दर्जा पुनः प्राप्त हुआ तथा आज इसके भी विभाग होकर इसका अध्ययन अध्यापन हो रहा है।

केन्द्रीय भारतीय चिकित्सा परिषद के नियमों के अनुसार आयुर्वेद शिक्षा में शालाक्य तन्त्र एक विशिष्ट विभाग के रूप में सभी महाविद्यालयों में स्थापित है। स्नातकोत्तर महाविद्यालयों में शालाक्य तन्त्र विभाग में भी नेत्र, नासा-मुख-कर्ण, दन्त एवं शिरोरोग जैसे उपविभाग हैं जहाँ सम्बन्धित स्नातकोत्तर पाठ्यक्रम चल रहे हैं, जो कि इसके निरन्तर विकास एवं उपयोगिता को दर्शाते हैं।

नेत्र रोग प्रकरण

अष्टांगसूत्रम् अनुसारं नेत्ररोगं वर्णितं अध्यायः

- 1. अक्षरोगोऽथ
- 2. अक्षरोगोऽथ
- 3. अक्षरोगोऽथ
- 4. अक्षरोगोऽथ
- 5. अक्षरोगोऽथ
- 6. अक्षरोगोऽथ
- 7. अक्षरोगोऽथ
- 8. अक्षरोगोऽथ
- 9. अक्षरोगोऽथ
- 10. अक्षरोगोऽथ
- 11. अक्षरोगोऽथ
- 12. अक्षरोगोऽथ
- 13. अक्षरोगोऽथ
- 14. अक्षरोगोऽथ
- 15. अक्षरोगोऽथ
- 16. अक्षरोगोऽथ
- 17. अक्षरोगोऽथ
- 18. अक्षरोगोऽथ
- 19. अक्षरोगोऽथ
- 20. अक्षरोगोऽथ
- 21. अक्षरोगोऽथ
- 22. अक्षरोगोऽथ
- 23. अक्षरोगोऽथ
- 24. अक्षरोगोऽथ
- 25. अक्षरोगोऽथ
- 26. अक्षरोगोऽथ
- 27. अक्षरोगोऽथ
- 28. अक्षरोगोऽथ
- 29. अक्षरोगोऽथ
- 30. अक्षरोगोऽथ



नेत्र रोग प्रकरण

अष्टांगसूत्रम् अनुसारं नेत्ररोगं वर्णितं अध्यायः

- 1. अक्षरोगोऽथ
- 2. अक्षरोगोऽथ
- 3. अक्षरोगोऽथ
- 4. अक्षरोगोऽथ
- 5. अक्षरोगोऽथ
- 6. अक्षरोगोऽथ
- 7. अक्षरोगोऽथ
- 8. अक्षरोगोऽथ
- 9. अक्षरोगोऽथ
- 10. अक्षरोगोऽथ
- 11. अक्षरोगोऽथ
- 12. अक्षरोगोऽथ
- 13. अक्षरोगोऽथ
- 14. अक्षरोगोऽथ
- 15. अक्षरोगोऽथ
- 16. अक्षरोगोऽथ
- 17. अक्षरोगोऽथ
- 18. अक्षरोगोऽथ
- 19. अक्षरोगोऽथ
- 20. अक्षरोगोऽथ
- 21. अक्षरोगोऽथ
- 22. अक्षरोगोऽथ
- 23. अक्षरोगोऽथ
- 24. अक्षरोगोऽथ
- 25. अक्षरोगोऽथ
- 26. अक्षरोगोऽथ
- 27. अक्षरोगोऽथ
- 28. अक्षरोगोऽथ
- 29. अक्षरोगोऽथ
- 30. अक्षरोगोऽथ

सुश्रुतानुसार नेत्ररोग वर्णित अध्याय

उत्तरतंत्र अध्याय

- 1 औषद्रविक अध्याय
- 2 सन्धिगतरोगविज्ञानीय
- 3 वर्त्मगतरोगविज्ञानीय
- 4 शुक्लगतरोगविज्ञानीय
- 5 कृष्णगतरोगविज्ञानीय
- 6 सर्वगतरोगविज्ञानीय
- 7 दृष्टिगतरोगविज्ञानीय
- 8 चिकित्सितप्रविभागविज्ञानीय
- 9 वाताभिष्यन्दप्रतिषेध (अन्यतोवात, वातपर्यय, शुष्काक्षिपाक चिकित्सा का वर्णन)
- 10 पित्ताभिष्यन्दप्रतिषेध (अम्लाध्युषित, शुक्तिका, धूमदर्शी चिकित्सा का वर्णन)
- 11 श्लेष्माभिष्यन्दप्रतिषेध (बलासग्रथित, पिष्टक, प्रक्लिन्न, नेत्रकण्डू, नेत्रकण्डूशोफ चिकित्सा)
- 12 रक्ताभिष्यन्दप्रतिषेध (सिरोत्पात, सिराहर्ष, अर्जुन, सव्रणशुक्र, अव्रणशुक्र, अजकाजात, नेत्रपाक, पूयालस, प्रक्लिन्नवर्त्म, अप्रक्लिन्नवर्त्म का वर्णन)
- 13 लेख्यरोगप्रतिषेध
- 14 भेद्यरोगप्रतिषेध
- 15 छेद्यरोगप्रतिषेध
- 16 पक्ष्मकोपप्रतिषेध
- 17 दृष्टिगतरोगप्रतिषेध
- 18 क्रियाकल्प अध्याय
- 19 नयनाभिधातप्रतिषेध अध्याय

अष्टांगहृदय अनुसार नेत्ररोग वर्णित अध्याय

उत्तरतंत्र अध्याय

- 8 वर्त्मरोगविज्ञानीय अध्याय
- 9 वर्त्मरोग प्रतिषेध अध्याय
- 10 सन्धिसितासितरोगविज्ञानीय
- 11 सन्धिसितासितरोग प्रतिषेध
- 12 दृष्टिरोगविज्ञानीयाध्याय
- 13 तिमिरप्रतिषेधाध्याय
- 14 लिंगनाशप्रतिषेधाध्याय
- 15 सर्वाक्षिरोगविज्ञानीयाध्याय
- 16 सर्वाक्षिरोगप्रतिषेधाध्याय (पिल्ल चिकित्सा, पूयालस में अग्निकर्म, नेत्र रोगों में पादशिराएं, नेत्र पथ्य अपथ्य वर्णन)

नेत्र रोग वर्णन

संदर्भ अध्यायः

1	चरक संहिता	-	च.चि. 26 (त्रिमूर्तीयचिकित्सा अध्याय)
2	सुश्रुत संहिता	-	सुश्रुत संहिता उत्तरतंत्र 1-19 अध्याय
3	अष्टांग हृदय	-	अ.हृ. उत्तरतंत्र 8-16 अध्याय
4	भावप्रकाश	-	नेत्ररोगाधिकार अध्याय 63
5	योगरत्नाकर	-	उत्तरार्ध नेत्ररोग अध्याय
6	चक्रदत्त संहिता	-	नेत्ररोगाधिकार अध्याय 58

नेत्ररोग विभाजन एवं संख्या निरूपण

चरकानुसार	-	4 (V, P, K, S), 96 (च.चि. 26)
सुश्रुतानुसार	-	76
अष्टांगहृदय	-	94
भावप्रकाश	-	78
योगरत्नाकर	-	78
विदेहानुसार	-	76
सात्यकि अनुसार	-	80
शारंगधर संहिता	-	94
कराल संहिता	-	76

4	76	78	80	94
↓	↓	↓	↓	↓
चरकानुसार	सुश्रुतानुसार विदेहानुसार	भावप्रकाश योगरत्नाकर	सात्यकि	अष्टांगहृदय शारंगधरसंहिता

चिकित्सिय विभाजन

दोषानुसार वर्गीकरण

सुश्रुतानुसार

सुश्रुतानुसार

वातिक	-	10	छेद्य	-	11
पैतिक	-	10	लेख्य	-	9
श्लेष्मिक	-	13	भेद्य	-	5 ← 52 साध्य
रक्तज	-	16	व्यध्य	-	15
सन्निपातिक	-	25	अशस्त्रकृतसाध्य(औषध चि. साध्य)	-	12
बाह्य	-	2	याप्य	-	7 ← याप्य
कुल योग	-	76	असाध्य	-	15
			बाह्य	-	2 ← 17 असाध्य

दोषानुसार वर्गीकरण

V	P	K	R	S	B
10	10	13	16	25	2

आश्रयानुसार वर्गीकरण

आश्रय	सुश्रुतानुसार	वाग्भट्टानुसार	भावप्रकाश / यो.र.
संधिगत	9	9	9
वर्त्मगत	21	24	21
शुक्लगत	11	13	11
कृष्णगत	4	5	4
सर्वगत	17	16	17
दृष्टिगत	12	27	14 (सनिमित्त व अनिमित्त लिंगनाश को दृष्टिगत रोग माना है)
बाह्य	2		
पक्ष्मगत			पक्ष्मकोप व पक्ष्मशात
	76	94	78

साध्यासाध्यता विभाजन

सुश्रुतानुसार

साध्य - 52

याप्य - 7

असाध्य - 17

आश्रयानुसार नामकरण

सन्धिगत नेत्र रोग

“पूयालसः सोपनाहः स्रावाः पर्वणिकाऽलजी।

क्रिमिग्रन्थिश्च विज्ञेयारोगाः सन्धिगता नव।।” सु.उ. 2/3

	सुश्रुतानुसार	सुश्रुतानुसार चिकित्सासूत्र	अष्टांग हृदय
1	पूयालस (S)	वेध्य	जलास्राव*
2	उपनाह (K)	भेद्य	कफास्राव*
3	पूयास्राव (S)	असाध्य	रक्तास्राव*
4	श्लेष्मास्राव (K)	असाध्य	पूयास्राव
5	रक्तास्राव (R)	असाध्य	उपनाह
6	पित्तास्राव (P)	असाध्य	पर्वणी
7	पर्वणी (R)	छेद्य	पूयालस
8	अलजी (S)	असाध्य	अलजी*
9	कृमिग्रन्थि (K)	भेद्य	कृमिग्रन्थि

*असाध्य (अष्टांग हृदयानुसार)

विमर्श

1 आचार्य सुश्रुत व आचार्य वाग्भट्ट दोनों ने सन्धिगत रोगों की संख्या 9 स्वीकार की है परन्तु वाग्भट्ट ने 'पित्तास्राव' के स्थान पर 'जलास्राव' का वर्णन किया है।

2 सुश्रुतानुसार

वातज	पित्तज	कफज	रक्तज	सन्निपातज
None	1	3	2	3
	पित्तास्राव	श्लेष्मास्राव उपनाह कृमिग्रन्थि	रक्तास्राव पर्वणी	पूयास्राव पूयालस अलजी

V	P	K	R	S
0	1	3	2	3

- 3 असाध्यता वर्णन— चतुर्विधस्राव एवं अलजी (Total 5) असाध्य हैं। (सुश्रुतानुसार)
- 4 अशसकृत औषध साध्य व वातज कोई भी सन्धिगत रोग नहीं होता। (सुश्रुत वर्गीकरण)

वर्त्मगत रोग—

1. "उत्संगिन्यथ कुम्भिका पोथक्यो वर्त्मशर्करा।
तथाऽर्शोवर्त्म शुष्कार्शस्तथैवांजननामिका।।
बहलं वर्त्म यंचापि व्याधिर्वर्त्मावबन्धकः।
क्लिष्टकर्दमवर्त्माख्यौ श्याववर्त्मतथैव च।
प्रक्लिन्नमपरिक्लिन्नं वर्त्म वातहतन्तु यत्।
अर्बुदं निमिषश्चापि शोणितार्शश्च यत स्मृतम्।।
लगणो विसनामा च पक्ष्मकोपस्तथैव च।
एकविंशतिरित्येते विकारा वर्त्मसंश्रया।।" सु.उ. 3/5-8
2. "उत्सङ्गिन्यथ कुम्भिका पोथकी वर्त्मशर्करा।
तथाऽर्शोवर्त्म शुष्कार्शस्तथैवांजनदूषिका।।
बहलं वर्त्म यञ्चापि तथाऽन्यो वर्त्मबन्धकः।
क्लिष्टवर्त्म तथा वर्त्मकर्दमः श्याववर्त्म च।
प्रक्लिन्नवर्त्माक्लिन्न वर्त्मवातहतञ्च यत्।
वर्त्मार्बुदं निमेषश्च शोणितार्शस्तथैव च।।
लगणो विसवर्त्मापि कुंचनं नाम तत्परम्।।
एकविंशतिरित्येते विकारा वर्त्मसंश्रया।। भा.प्र. नेत्ररोग 63/76

विमर्श — भावप्रकाश ने सुश्रुतोक्त 'अंजननामिका' व 'पक्ष्मकोप' के स्थान पर क्रमशः 'अंजनदूषिका' व 'कुंचन' का वर्णन किया है।

3. "तेषुवर्त्मगदाः प्रोक्ताश्चुर्विंशति संज्ञकाः।
कृच्छ्रोन्मीलः पक्ष्मशातः कफोत्क्लिष्टश्च लोहितः।
अरुद्धनिमेषः कथितो रक्तोत्क्लिष्टः कुकूणकः।।
पक्ष्मार्शः पक्ष्मरोधश्च पित्तोत्क्लिष्ट च पोथकी।
क्लिष्टवर्त्मा च बहलः पक्ष्मोत्संगस्तथाबुर्दम्।।
कुम्भिका सिकतावर्त्म लगणोऽञ्जननामिका।
कर्दमः श्याववर्त्मा च विसवर्त्मा तथाऽलजी।।
उत्क्लिष्ट वर्त्मेति गदाः प्रोक्ता वर्त्मसमुदभवा।।"

शा.सं. पूर्वखण्ड अध्याय 7/153-156

सुश्रुतोक्त		दोषविमर्श	चिकित्सा	वाग्भट्टोक्त	चिकित्सा											
1	उत्सिगिनी	सन्निपातिक	लेख्य	1 कृच्छ्रोन्मीलन	भेषजसाध्य											
2	कुम्भिका	सन्निपातिक	लेख्य	2 निमेष	असाध्य											
3	पोथकी	कफज	लेख्य	3 वातहतवर्त्म	असाध्य											
4	वर्त्मशर्करा	सन्निपातिक	लेख्य	4 कुम्भीक रोग	शस्त्रसाध्य											
5	अर्शोवर्त्म	सन्निपातिक	छेदय	5 पित्तोक्ल्लिष्ट	शस्त्रसाध्य											
6	शुष्कार्श	सन्निपातिक	छेदय	6 पक्ष्मशात	शस्त्रसाध्य											
7	अंजननामिका	रक्तज	भेदय	7 पोथकी	शस्त्रसाध्य											
8	बहल वर्त्म	सन्निपातिक	लेख्य	8 कफोत्क्ल्लिष्ट	शस्त्रसाध्य											
9	वर्त्मबन्धक	सन्निपातिक	लेख्य	9 लगण	शस्त्रसाध्य											
10	क्ल्लिष्टवर्त्म	रक्तज	लेख्य	10 उत्संगा	शस्त्रसाध्य											
11	कर्दमवर्त्म	सन्निपातिक	लेख्य	11 उत्क्ल्लिष्ट	शस्त्रसाध्य											
12	श्याववर्त्म	सन्निपातिक	लेख्य	12 अर्शोवर्त्म	असाध्य											
13	प्रक्ल्लिन्नवर्त्म	कफज	अशस्त्रकृत	13 अंजननामिका	शस्त्रकर्मसाध्य											
14	अपरिक्ल्लिन्नवर्त्म	सन्निपातिक	अशस्त्रकृत	14 विसवर्त्म	शस्त्रकर्मसाध्य											
15	वातहतवर्त्म	वातज	असाध्य	15 उत्क्ल्लिष्ट	शस्त्रकर्मसाध्य											
16	अर्बुद	सन्निपातिक	छेदय	16 श्याववर्त्म	शस्त्रकर्मसाध्य											
17	निमेष	वातज	असाध्य	17 शिल्लिष्टवर्त्म	शस्त्रकर्मसाध्य											
18	शोणितार्श	रक्तज	असाध्य	18 सिकतावर्त्म	शस्त्रकर्मसाध्य											
19	लगण	कफज	भेदय	19 कर्दमवर्त्म	शस्त्रकर्मसाध्य											
20	विसवर्त्म	सन्निपातिक	भेदय	20 बहलवर्त्म	शस्त्रकर्मसाध्य											
21	पक्ष्मकोप	सन्निपातिक	याप्य	21 कुकूणक	शस्त्रकर्मसाध्य											
<table border="1"> <thead> <tr> <th>V</th> <th>P</th> <th>K</th> <th>R</th> <th>S</th> </tr> </thead> <tbody> <tr> <td>2</td> <td>0</td> <td>3</td> <td>3</td> <td>13</td> </tr> </tbody> </table>				V	P	K	R	S	2	0	3	3	13	22	पक्ष्मोपरोध	याप्य
				V	P	K	R	S								
				2	0	3	3	13								
23	अलजी	शस्त्रकर्म														
24	अर्बुदवर्त्म	शस्त्रकर्म														

विमर्श

- 1) आचार्य वाग्भट्ट ने कृच्छ्रोन्मीलन, पित्तोक्ल्लिष्ट, पक्ष्मशात, कफोत्क्ल्लिष्ट, उत्क्ल्लिष्ट, शिल्लिष्टवर्त्म, कुकूणक, पक्ष्मोपरोध (सुश्रुत पक्ष्मकोप समकक्ष) व अलजी आदि रोगों का सुश्रुत से अतिरिक्त वर्णन किया है।
- 2) आचार्य भावप्रकाश ने पक्ष्म संश्रित दो रोगों का अधिष्ठान पृथक स्वीकार किया है व वर्त्मगत रोगों में 'पक्ष्मकोप' व 'पक्ष्मशात' को समावेशित नहीं किया है। 'कुंचन' रोग का अतिरिक्त वर्णन वर्त्मगत रोगों में किया है।
- 3) सुश्रुतानुसार समस्त लेख्य रोग (9) वर्त्मगत हैं व पित्तज वर्त्मगत रोग नहीं होता है। वेध्य वर्त्मगत भी कोई रोग नहीं होता।
- 4) आचार्य सुश्रुतोक्त वर्णित 'पक्ष्मकोप' के समान आचार्य वाग्भट्ट ने 'पक्ष्मोपरोध' रोग का वर्णन किया है व दोनों रोग याप्य हैं।
- 5) शारंगधर ने लोहित, अरुड, निमेष, रक्तोत्क्ल्लिष्ट, पक्ष्मार्श, 'पक्ष्मोत्संग' आदि वर्त्मगत रोगों का अतिरिक्त वर्णन कर कुल संख्या 24 बताई है।
- 6) आचार्य वाग्भट्ट ने 'कुकूणक' रोग को वर्त्मगत रोगों में समावेशित किया है जबकि आचार्य सुश्रुत ने नेत्रगत रोगों में गणना न कर इसका पृथक वर्णन 'नयनाभिघातप्रति-षेधाध्याय' (सु.उ.तं. 19) में किया है।
- 7) हृदयकार ने 'अलजी' रोग को संधिगत रोगों व वर्त्म रोगों दोनों में इसकी गणना कर वस्तुतः दो पृथक रोग 'अलजी' नाम से लिखे हैं।

8) आचार्य वाग्भट्ट ने 'उत्क्लिष्ट' रोग की गणना दो बार की है अर्थात् वाग्भट्टोक्त 24 वर्त्न रोगों में 'उत्क्लिष्ट' दो बार आया है।

शुक्लगत रोग -

सुश्रुतानुसारः

'प्रस्तारिशुक्ल क्षतजाधिमांस स्नाय्वर्मसंज्ञाः खलुपंच रोगाः।

स्युः शुक्तिकाचार्जुनपिष्टकौ च जालं सिरणां पिडकाश्च थाः स्युः॥

रोगा बलासग्रथितेन सार्द्धमेकादशाक्ष्णोः खलु शुक्ल भागे॥

	सुश्रुतोक्त	दोषविमर्श	चिकित्सा		वाग्भट्टोक्त	चिकित्सा
1	प्रस्तारि अर्म	सन्निपातज	छेदय	1	प्रस्तारि अर्म	शस्त्रकर्म
2	शुक्ल अर्म	कफज	छेदय	2	शुक्लार्म	शस्त्रकर्म
3	क्षतज अर्म	रक्तज	छेदय	3	शोणितार्म	शस्त्रकर्म
4	अधिमांसज अर्म	सन्निपातज	छेदय	4	अधिमांसज अर्म	शस्त्रकर्म
5	स्नायु अर्म	सन्निपातज	छेदय	5	स्नायु अर्म	शस्त्रकर्म
6	शुक्तिका	पित्तज	अशस्त्रकृतसाध्य	6	शुक्तिका	औषधसाध्य
7	अर्जुन	रक्तज	अशस्त्रकृतसाध्य	7	अर्जुन	औषधसाध्य
8	पिष्टक	कफज	अशस्त्रकृत	8	पिष्टक	औषधसाध्य
9	सिराजाल	रक्तज	छेदय	9	सिराजाल	शस्त्रकर्म
10	सिरापिडका	सन्निपातज	छेदय	10	सिराजपिटिका	शस्त्रकर्म
11	बलासग्रथित	कफज	अशस्त्रकृत	11	सिरोत्पात	औषधसाध्य
				12	सिराहर्ष	औषधसाध्य
				13	बलासग्रथित	औषधसाध्य

सुश्रुतानुसारः

V	P	K	R	S
0	1	3	3	4
	शुक्तिका	पिष्टक बलास ग्रथित शुक्लार्म	अर्जुन सिराजाल क्षतज अर्म	प्रस्तारि अर्म अधिमांसज अर्म स्नायु अर्म सिरापिडिका

शुक्लगत रोग का चिकित्सा

7	+	4
↓		↓
छेदय		अशस्त्रकृत साध्य/औषधसाध्य

विमर्श:-

- 1) आचार्य सुश्रुत ने 'सिरोत्पात' एवं 'सिराहर्ष' को सर्वगत रोग माना है जबकि वाग्भट्ट ने इन्हें शुक्लगत रोग स्वीकार किया है।
- 2) शार्दूलगर्भर संहिता में 'बलासग्रथित' के स्थान पर 'कफज ग्रन्थि' शब्द प्रयोग किया गया है।
- 3) शुक्लगत वातज रोग कोई नहीं होता।

कृष्णगत नेत्ररोग:

"यत्सव्रणं शुक्रमथाव्रणं वा पाकात्ययश्चाप्यजका तथैव।

चत्वार एतेऽभिहिता विकाराः कृष्णाश्रयाः संग्रहतः पुरस्तात्।।" सु.उ. 5/3

	सुश्रुतानुसार	दोषविमर्श	चिकित्सा		वाग्भट्टानुसार	चिकित्सा
1	सव्रण शुक्र	रक्तज	असाध्य	1	क्षतजशुक्र	असाध्य
2	अव्रण शुक्र	रक्तज	अशस्त्रकृत	2	शुद्धशुक्र	साध्य
3	अक्षिपाकात्यय	सन्निपातज	असाध्य	3	सिराजशुक्र	असाध्य
4	अजकाजात	रक्तज	असाध्य	4	अजका	असाध्य
				5	पाकात्यय शुक्र	असाध्य

विमर्श:

- 1) योगरत्नाकर ने 'सिराजशुक्र' को 'सिरासंग' कहा है।
- 2) आचार्य वाग्भट्ट ने 'सिराजशुक्र' का अतिरिक्त वर्णन किया है व 'अव्रणशुक्र' के अतिरिक्त सभी रोग असाध्य माने हैं।

सुश्रुतानुसार:

V	P	K	R	S
0	0	0	3	1

- 3) आचार्य वाग्भट्ट ने 'अक्षिपाकात्यय' (सुश्रुतानुसार) का वर्णन कृष्णगत रोगों में न कर सर्वगत रोगों में अक्षिपाकात्यय को स्वीकार किया है।

सर्वगत नेत्ररोग

सुश्रुतानुसार-

- "स्यन्दास्तु चत्वार इहोपदिष्टास्तावन्त एवेह तथाऽधिमन्थाः।
शोफान्वितोऽशोफयुतश्च पाकावित्येवमेते दशसम्प्रदिष्टाः।।
हताधिमन्थोऽनिलपर्ययश्चशुष्काक्षिपाकोऽन्यत एव वातः।
दृष्टिस्तथाऽम्लाध्युषिता सिराणमुत्पातहर्षावपि सर्वभागाः।। सु.उ. 6/3-4
- "सर्वाक्षिरोगाश्चाष्टौ स्युस्तेषु वातविपर्ययः।
अल्पशोफोऽन्यतोवातस्तथा पाकात्ययः स्मृतः।
शुष्काक्षिपाकश्च तथा शोफोऽध्युषित एव च।।
हताधिमन्थ इत्येते रोगाः सर्वाक्षिसम्भवाः।।" शा.सं. पूर्वखंड 7/169-170

	सुश्रुतोक्त	दोषविमर्श	चिकित्सा		वाग्भट्टानुसार (16)	चिकित्सा
1-4	चार अभिष्यन्द	VPKR	सभी वेध्य	1-4	अभिष्यन्द VPKR	साध्य
5-8	चार अधिमन्थ	VPKR	सभी वेध्य	5-8	अधिमन्थ VPKR	साध्य
9	सशोफ अक्षिपाक	सन्निपातज	वेध्य	9	सशोफपाक	साध्य
10	अशोफ अक्षिपाक	सन्निपातज	वेध्य	10	अल्प शोफपाक	साध्य
11	हताधिमन्थ	वातज	असाध्य	11	हताधिमन्थ	असाध्य
12	वातपर्यय	वातज	वेध्य	12	वातपर्यय	साध्य
13	शुष्काक्षिपाक	वातज	अशस्रकृत	13	शुष्काक्षिपाक	साध्य
14	अन्यतोवात	वातज	वेध्य	14	अन्यतोवात	साध्य
15	अम्लाध्युषित	पित्तज	अशस्रकृत	15	अम्लोषित	साध्य
16	सिरोत्पात	रक्तज	वेध्य	16	अक्षिपाकात्यय	असाध्य
17	सिराहर्ष	रक्तज	वेध्य			

V	P	K	R	S	
6	3	2	4	2	= 17 योग

विमर्श-

1. सुश्रुतोक्त 15 व्यध्य रोगों में 14 रोग सर्वगत हैं व इसके अतिरिक्त सन्धिगत रोग 'पूयालस' व्यध्य है।
2. सुश्रुतोक्त कृष्णगत 'अक्षिपाकात्यय' रोग को आचार्य वाग्भट्ट ने सर्वगत स्वीकार किया है।
3. सुश्रुतोक्त 'अम्लाध्युषित' रोग को वाग्भट्ट ने 'अम्लोषित' कहा है।
4. नामकरण में 'भावप्रकाश' व 'योगरत्नाकर' सुश्रुत के समर्थन कर संख्या 17 बताई है। आचार्य शार्ङ्गधर ने सर्वगत रोग संख्या 8 बताई है व अभिष्यन्द व अधिमन्थ का वर्णन पृथक किया है, परन्तु अन्य नामकरण वाग्भट्ट समान ही है।
5. आचार्य वाग्भट्ट ने 'दृष्टिगत' रोगों का वर्णन करने के पश्चात 'सर्वगत' नेत्र रोगों का वर्णन किया है जबकि आचार्य सुश्रुत ने दृष्टिगत रोगों से पूर्व में 'सर्वगत' रोगों का वर्णन किया है।
6. सर्वगत नेत्र रोगों (सुश्रुतोक्त) की संख्या 17 है व इनमें शुष्काक्षिपाक, अम्लाध्युषित (दोनों अशस्रकृत औषधसाध्य) व हताधिमन्थ (असाध्य) के अतिरिक्त समस्त रोग 'व्यध्य' हैं।

दृष्टिगत रोग-

“षट् लिंगनाशाः षडिमे च रोगा दृष्टयाश्रयाः षट् च षडेव च स्युः ।
 तथा नरः पित्तविदग्धदृष्टिः कफेनवान्यस्त्वथ धूमदर्शी ॥
 यो ह्रस्वजाड्यो नकुलान्धता च गम्भीरसंज्ञा च तथैवदृष्टिः ॥” सु.उ. 7/34
 “अष्टधा दृष्टिरोगाः स्युस्तेषु पित्तविदग्धकम् ।
 अम्लपित्तविदग्धं चतथैवोष्ण विदग्धकम् ॥
 नकुलान्धं धूसरान्धं रात्र्यान्यं ह्रस्वदृष्टिकः ॥
 गम्भीर दृष्टिरित्येते रोगा दृष्टिगता मताः ॥” शा.पू. 7/166-167

भावप्रकाश मत-

सुश्रुतोक्त 12 रोग व

- 13) सनिमित्तज लिंगनाश ← 14 संख्या बताई है ।
 14) अनिमित्तज लिंगनाश

	सुश्रुतानुसार	दोष	चिकित्सा		वाग्भट्टानुसार	चिकित्सा
1-6	षट्लिंगनाश			1-7	लिङ्गनाश	
1	वातज	V	याप्य	1	वातज	असाध्य
2	पित्तज	P	याप्य	2	पित्तज	असाध्य
3	कफज	K	याप्य	3	कफज	साध्य
4	रक्तज	R	याप्य	4	रक्तज	असाध्य
5	सन्निपातज	S	याप्य	5	सन्निपातज	असाध्य
6	संसर्गज या परिम्लायी काच/लिंगनाश	(संसर्गज पित्तज)	याप्य	6	संसर्गज	असाध्य
				7	औपसर्गिक	असाध्य
7	पित्तविदग्ध दृष्टि	पित्तज	अशस्त्रकृत	8-13	षट्कांच	सभी याप्य
8	श्लेष्मविदग्ध दृष्टि	कफज	अशस्त्रकृत	14-19	षट्तिमिर	सभी साध्य
9	धूमदर्शी	पित्तज	अशस्त्रकृत	20	गम्भीरा दृष्टि	असाध्य
10	ह्रस्वजाड्य	पित्तज	असाध्य	21	ह्रस्वजा दृष्टि	असाध्य
11	नकुलान्ध	सन्निपातज	असाध्य	22	नकुलान्ध	याप्य
12	गम्भीरिका	वातज	असाध्य	23	पित्तविदग्धदृष्टि	साध्य
				24	उष्णविदग्धदृष्टि	साध्य
				25	अम्लविदग्धदृष्टि	साध्य
				26	दोषान्ध	साध्य
				27	धूमर	साध्य

विमर्श-

1. आचार्य सुश्रुत ने षट्लिंगनाश का वर्णन किया है यथा - V, P, K, R, S व संसर्गज जबकि आचार्य वाग्भट्ट ने सप्त लिंगनाश का वर्णन कर "औपसर्गिक लिंगनाश" का अतिरिक्त वर्णन किया है ।
2. शार्ङ्गधर संहिता में 'अष्ट' 8 दृष्टिरोग माने गए हैं परंतु तिमिर, काच एवं लिंगनाश की गणना इन आठ रोगों में नहीं की है ।
3. आचार्य सुश्रुत एवं अन्य आचार्यों ने कफजलिंगनाश की विशिष्ट चिकित्सा (शल्य कर्म) का विस्तृत वर्णन किया है ।
4. आचार्य वाग्भट्ट ने 'काच' एवं 'तिमिर' के छः भेद बताकर उनकी गणना भी दृष्टिगत रोगों में की है ।

5. आचार्य वाग्भट्ट ने निम्न रोगों का सुश्रुतोक्त रोगों के अतिरिक्त वर्णन किया है -

1. हृस्वजा दृष्टि (सुश्रुतोक्त हृस्वजाड्य रोग समान लक्षण)
2. उष्ण विदग्ध दृष्टि
3. अम्ल विदग्ध दृष्टि
4. दोषान्ध व 'धूमदर्शी' के स्थान पर 'धूमर' शब्द का प्रयोग किया है।

6. सुश्रुतानुसार -

V	P	K	R	S	
2	5	2	1	2	= 12 योग

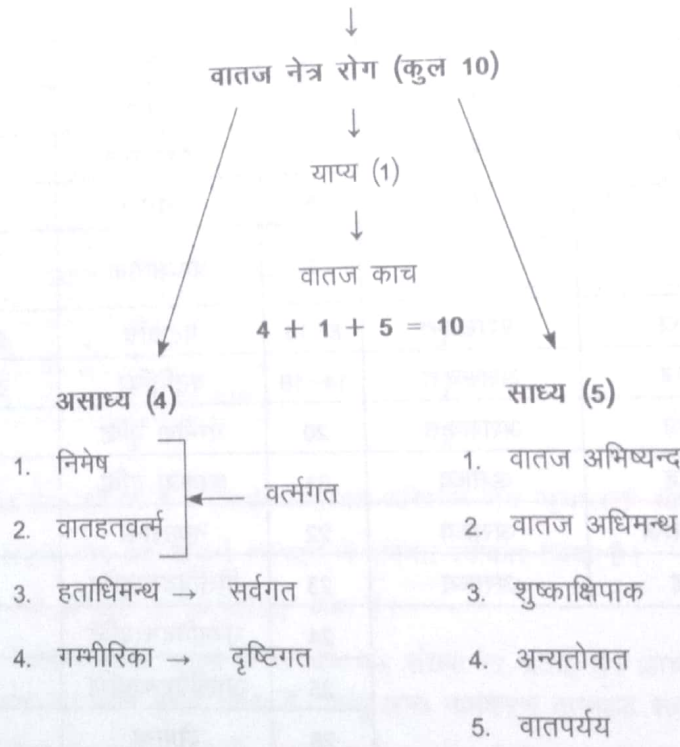
7. आचार्य भावप्रकाश/यो0र0 ने दृष्टिगत रोगों की संख्या 14 स्वीकार की है।

8. आचार्य सुश्रुत ने नेत्रगत याप्य रोगों की संख्या 7 बताई है।

यथा : 6 प्रकार के लिंगनाश + पक्ष्म कोप कुल → 7 योग

9. आचार्य सुश्रुत ने 'नकुलान्ध्य' को असाध्य बताया है जबकि आचार्य वाग्भट्ट ने इसे याप्य बताया है।

दोषानुसार नेत्र रोग विभाजन



“हताधिमन्थो निमिषो दृष्टिर्गम्भीरिका च या।

यंच वातहतं वर्त्म न ते सिध्यन्ति वातजाः।।

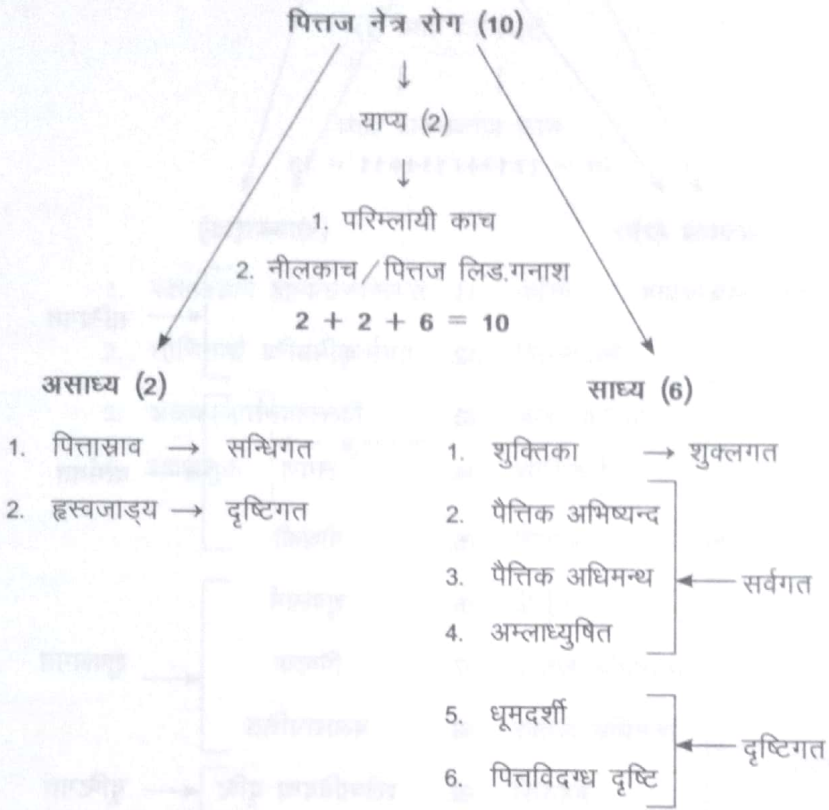
याप्योऽथतन्मयः काचः साध्याः स्यु साम्य मारुताः।

शुष्काक्षिपाकाधीमन्थस्यन्दमारुतपर्ययाः।।”

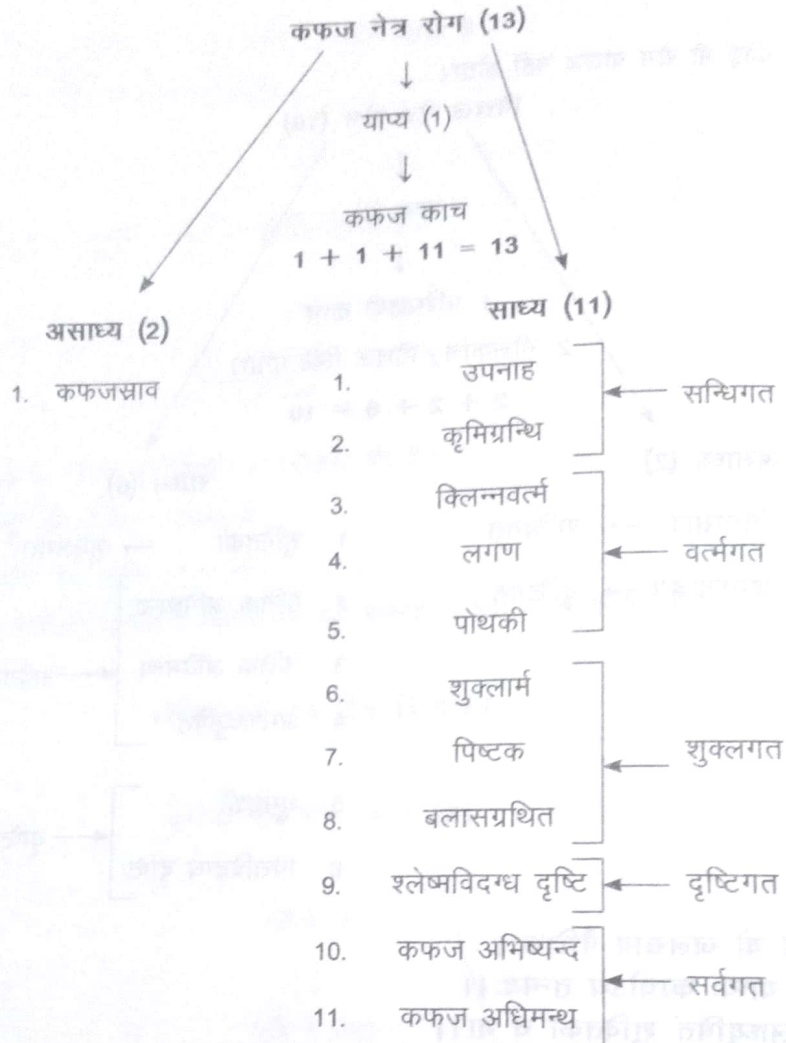
सु.उ.1/29-30

विमर्श-

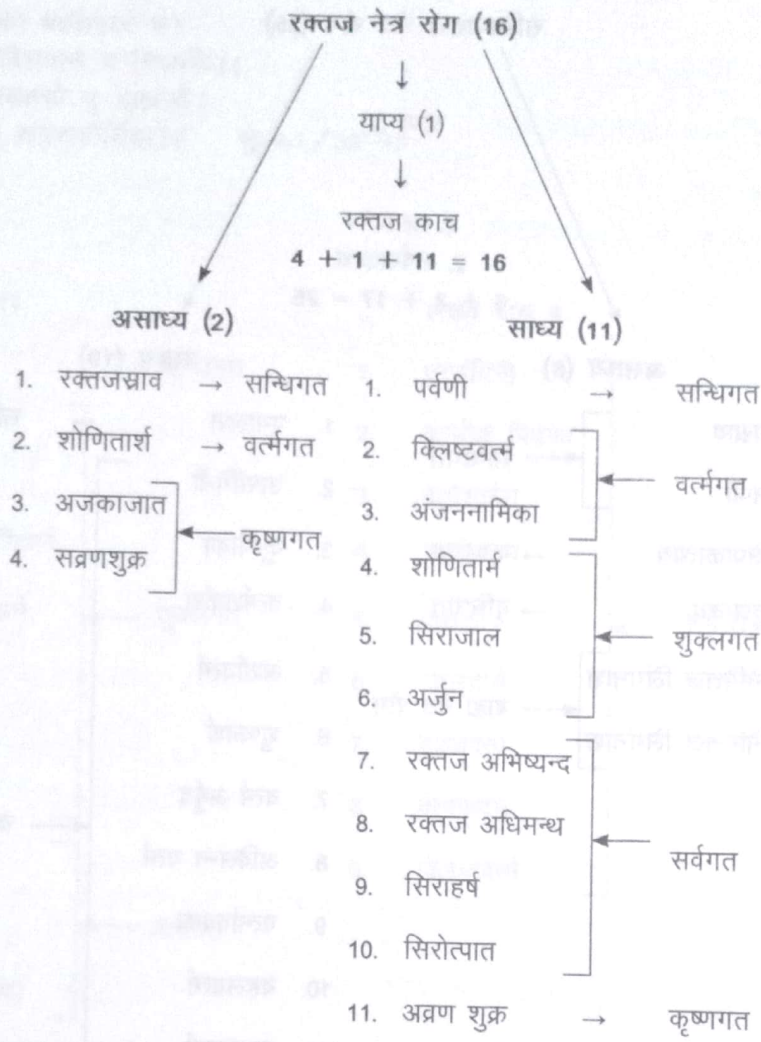
1- 'सन्धिगत' एवं 'शुक्लगत' कोई भी रोग वातज नहीं होता।



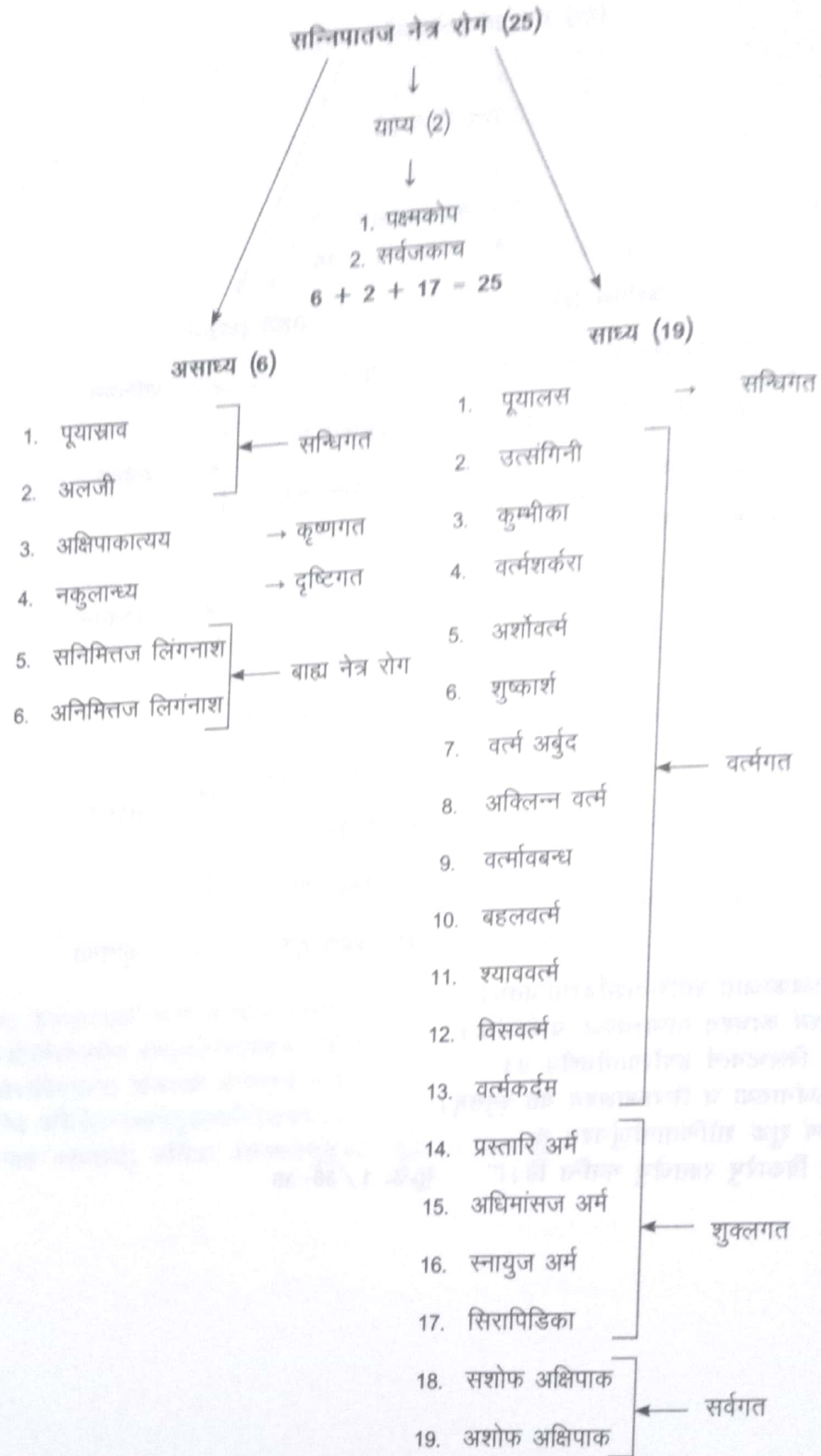
“असाध्यो ह्रस्वजाड्यो यो जलस्राव पैत्तिकः।
परिम्लायी च नीलश्च याप्यः काचोऽथ तन्मयः॥
अभिष्यन्दोऽधिमन्थोऽम्लाध्युषितं शुक्तिका च या॥
दृष्टिःपित्तविदग्धा च धूमदर्शी च सिद्ध्यति॥”सु.उ. 1/31-32



“असाध्यः कफजःस्रावो याप्य काचश्च तन्मयः ।
अभिष्यन्दोऽधिमन्थश्च बलासग्रन्थितञ्च यत् ॥
दृष्टिःश्लेष्मविदग्धाच्च पोथकयो लगणश्च यः ।
क्रिमिग्रन्थि परिक्लिन्नवर्त्मशुक्लार्मपिष्टकाः ॥
श्लेष्मोपनाहः साध्यास्तु कथिताः श्लेष्मजेषुतु ॥” सु.उ. 1/33-35



“रक्तस्रावोऽजकाजातं शोणितार्शोव्रणान्वितम् ।
 शुक्रं न साध्यं काचश्च याप्यस्तज्जः प्रकीर्तितः ।
 मन्थस्यन्दौ क्लिष्टवर्त्म हर्षोत्पातौतथैव च ।
 सिराजाताऽजनाख्या च सिराजालश्च यत स्मृतम् ।
 पर्वण्यथाव्रणं शुक्रं शोणितार्मर्जुनश्च चः ।
 एते साध्या विकारेषु रक्तजेषु भवन्ति हि ॥” सु.उ. 1/36-38



पूयास्रावो नाकुलान्ध्यमक्षिपाकात्ययोऽलजी ।
 असाध्याः सर्वजायाप्याः काचःकोपश्च पक्ष्मणः ॥
 वर्त्मावबन्धो यो व्याधिः सिरासु पिडकाच या ।
 प्रस्तार्यर्माधिमांसार्मस्नाय्वर्मोत्सङ्गिनी च या ॥
 पूयालसश्चार्बुदश्च श्वावकर्दम वर्त्मनी ।
 तथाऽर्शोवर्त्म शुष्कार्शः शर्करावर्त्म यञ्च वै ॥

सशोफश्चाप्यशोफश्चपाको बहलवर्त्म च।
 अविलन्नवर्त्म कुम्भीका विसवर्त्म च सिध्यति।।
 सन्निमित्तोऽनिमित्तश्चद्वावसाध्यौ तु बाह्यजौ।
 षट्सप्ततिर्विकारणामेषां संग्रहकीर्तिता।।” सु.उ.1/39-43

चिकित्सा अनुसार विभाजन

छेद्य रोग 11	लेख्य रोग 9
1. पर्वणी → सन्धिगत	1. उत्संगिनी
2. प्रस्तारिअर्म	2. कुम्भीक पिडका
3. शुक्लार्म	3. वर्त्मशर्करा
4. रक्तार्म / शोणितार्म	4. वर्त्मावबन्ध
5. अधिमांसज अर्म ← शुक्लगत	5. पोथकी ← समस्त वर्त्मगत
6. स्नायु अर्म	6. बहलवर्त्म
7. सिराजाल	7. श्याववर्त्म
8. सिरापिडिका	8. वर्त्मकर्दम
9. अर्शोवर्त्म	9. क्लिष्टवर्त्म
10. शुष्कार्श ← वर्त्मगत	
11. अबुर्द (वर्त्माबुर्द)	
भेद्यरोग-5	व्यध्य रोग-15
1. उपनाह	1. पूयालस
2. कृमिग्रन्थि ← सन्धिगत	2-5. अभिष्यन्द (VPKR)
3. अंजननामिका	6-9. अधिमन्थ (VPKR)
4. लगण	10. सशोफ अक्षिपाक
5. विसवर्त्म ← वर्त्मगत	11. अशाफ अक्षिपाक ← सर्वगत
	12. अन्यतोवात
	13. वातपर्यय
	14. सिरोत्पात
	15. सिराहर्ष

विमर्श:-

1. समस्त लेख्य रोग वर्त्मगत हैं।
2. व्यध्य रोग (संख्या 15) में 14 रोग सर्वगत हैं + 1 'पूयालस'।

अशसकृतसाध्य/औषध

साध्य रोग (12)

- | | |
|---------------------------------------|------------|
| 1. अक्लिन्न वर्त्म/अपरिक्लिन्न वर्त्म | ← वर्त्मगत |
| 2. प्रक्लिन्न वर्त्म | |
| 3. शुक्तिका | ← शुक्लगत |
| 4. अर्जुन | |
| 5. पिष्टक | |
| 6. बलासग्रथित | → कृष्णगत |
| 7. अव्रणशुक्र | |
| 8. शुष्काक्षिपाक | ← सर्वगत |
| 9. अम्लाध्युषित | |
| 10. कफविदग्धदृष्टि | ← दृष्टिगत |
| 11. पित्तविदग्धदृष्टि | |
| 12. धूमदर्शी | |

असाध्य रोग (17)

- | | |
|-----------------------|--------------|
| 1. जलास्राव | ← 5 संधिगत |
| 2. कफजस्राव | |
| 3. रक्तजस्राव | |
| 4. पूयास्राव | |
| 5. अलजी | |
| 6. शोणितार्श | ← 3 वर्त्मगत |
| 7. निमेष | |
| 8. वातहतवर्त्म | |
| 9. सव्रणशुक्र | ← 3 कृष्णगत |
| 10. अजकाजात | |
| 11. अक्षिपाकात्यय | |
| 12. हतादिमन्थ | 1 सर्वगत |
| 13. गम्भीरिका | ← 3 दृष्टिगत |
| 14. ह्रस्वजाड्य | |
| 15. नकुलान्ध्य | |
| 16. सनिमित्तज लिंगनाश | ← 2 बाह्य |
| 17. अनिमित्तज लिंगनाश | |

याप्य नेत्र रोग (7)

- | | |
|------------------|--------------|
| 1. वातिक काच | ← 6 दृष्टिगत |
| 2. पैतिक काच | |
| 3. कफज काच | |
| 4. रक्तज काच | |
| 5. त्रिदोषज काच | |
| 6. परिम्लायी काच | |
| 7. पक्ष्मकोप | → 1 वर्त्मगत |

सुश्रुतानुसार नेत्र रोग चिकित्सा का निर्देश:-

“छेद्यास्तेषु दशैकश्च नव लेख्याः प्रकीर्तिताः ।
भेद्याः पंच विकाराः स्युर्व्यध्याः पंचदशैव तु ॥
द्वादशाशसकृत्याश्च याप्याः सप्त भवन्ति हि ।
रोगा वर्जयेतव्याः स्युर्दश पञ्च च जानता ॥
असाध्यौ वा भवेतां तु याप्यौ चागुन्तुजसंज्ञितौ ॥” सु.उ. 8/4-5 (चिकित्साप्रविभाग अध्याय)

छेद्यरोग-

“अर्शोऽन्वितं भवति वर्त्मतु यत्तथाऽर्शः शुष्कं तथाऽबुर्दमथोपिडकाः सिराजाः ।
जालं सिराजमपिपंचविधं तथाऽर्म छेद्या भवन्ति सह पर्वणिकामयेन ॥” सु.उ. 8/6

लेख्यरोग-

उत्सङ्गि गनी बहलकर्दभवर्त्मनी च श्यावञ्च यंच पठितं त्विह बद्धवर्त्म ।
विलष्टंच पोथकीयुतं खलु यञ्चवर्त्म कुम्भीकिनी च सहशर्करया च लेख्याः ॥” सु.उ. 8/7

भेद्य/व्यध्य एवं अशसकृत रोग-

“श्लेष्मोपनाहलगणौ च बिसंचभेद्याग्रन्थिश्च यः कमिकृतोऽंजननामिका च ।
आदौ सिरानिगदितास्तु ययोः प्रयोगे पाकौ च यौ नयनयोः पवनोऽन्यतश्च ॥
पूयालसानिलविपर्ययमन्थ संज्ञाः स्यन्दास्तु यान्त्युपशमं हि सिराव्यधेन ।
शुष्काक्षिपाकफपित्तविदग्धदृष्टिष्वम्लाख्य शुक्रसहितार्जुनपिष्टकेषु ।
अक्लिन्नवर्त्महुतभुग्ध्वजदर्शिश्चुक्ति प्रक्लिन्नवर्त्मसु तथैव बलाससंज्ञे ।
आगन्तुनाऽऽमययुगेन च दूषितायांदृष्टौन शस्रपतनं प्रवदन्ति तज्ज्ञाः ॥ सु.उ. 8/8-10

याप्य एवं असाध्य रोग निर्देश-

“सम्पश्यतः षडपि येऽभिहितास्तु काचास्तेपक्ष्मकोपसहितास्तु भवन्ति याप्याः ।
चत्वारएवपवनप्रभवास्त्वसाध्या द्वौ पित्तजौ निमित्तज एक एव ॥
अष्टार्द्धका रूधिरजाशय गदासिदोषास्तावन्त एव गदितावपि बाह्यजौ द्वौ । सु.उ. 8/11

नेत्र रचना शरीर

“विद्याद द्वयङ्गुलबाहुल्यं स्वाङ्गुष्ठोदरसमितम् ।
द्वयङ्गुल सर्वतः सार्द्धं भिषङ्गनयनबुदबुदम् ॥
सुवृतं गोस्तनाकारं सर्वभूतगुणोदभवम् ॥
पलं भुवोऽग्नितो रक्तं वातात् कृष्णं सितं जलात् ।
आकाशादश्रुमार्गाश्च जायन्ते नेत्रबुदबुदे ॥” सु.उ. 1/10-11

- नेत्र की मोटाई सामने से पीछे की तरह दो अंगुल व एक से दूसरी तरफ का माप ढाई अंगुल जानना चाहिए। (यह प्रमाण अंगुष्ठ के उदर (मध्य) भाग के समान होता है।)
- इसी तरह इस नेत्रगोलक को वृत्ताकार तथा गौ के स्तन के आकार का भी जानना चाहिए।
- इसके अतिरिक्त नेत्र को पंचमहाभूतों के गुणों से उत्पन्न समझना चाहिए यथा नेत्र बुदबुद में पृथिवी से मांसल भाग, अग्नि से पित्तधर्मी रक्तवर्ण का भाग, वायु से कृष्णभाग, जल से नेत्र का श्वेत भाग व आकाश से अश्रुमार्ग की उत्पत्ति होती है।

डल्हन टीका - “तत्र सर्वेषूत्तमाङ्गस्थेषु संख्यादिभिर्वाच्येषु नयनगतरोगाभिधानं, सवेन्द्रियाणां मध्ये नयनस्य प्रधानत्वात्; तत्रापि नयनस्य पटलव्यघनिमित्तमन्तः, प्रवेशायाम विस्तरैर्मानमाकारं च दर्शयन्नाह - विद्यादित्यादि। द्वयङ्गुलबाहुल्यमिदमन्तः प्रवेशप्रमाणं, द्वयङ्गुलमानमाह - स्वाङ्गुष्ठोदरसमितं; एतेनैतदुक्तं भवति - स्वाङ्गुष्ठोदरसमितं यदङ्गुलं तदङ्गुलद्वयप्रमाणं नेत्रबुदुदरयान्तः - प्रवेशं विद्यात्। द्वयङ्गुलं - सार्द्धमिति अर्धतृतीयाङ्गुलमित्यर्थः। सर्वत इति आयामतो विस्तरश्चेत्यर्थः। नयन बुदबुदम नेत्रगोलकः। सर्वभूतगुणोदभवं सर्वभूतेभ्यस्तद्गुणेभ्यश्चोदभवो यस्यतत्तथाविचं; सर्वभूतेभ्यस्तावन्नेत्रबुदबुदं सिरासनयवस्थि सहितं साश्रुमार्गचोत्पन्नं तद्गुणेभ्यश्च रक्तसितकृष्णगुणा उत्पन्नाः। एतेन गुणवद्भूतोत्पन्नमित्यर्थः। केचिद्गुणशब्देन भूतप्रसादं कथयन्ति, तच्च व्याख्यानं जेज्जटाय न रोचते ॥”

दृष्टि विमर्श -

“दृष्टिं चात्र तथा वक्ष्ये यथा ब्रूयाद्विशारदः।

नेत्रायामत्रिभागं तु कृष्णमण्डलमुच्यते ॥

कृष्णात् सप्तममिच्छन्ति दृष्टिं दृष्टिविशारदाः ॥” सु.उ. 1/12

- विदेह जैसे विद्वानों द्वारा वर्णित व्याख्यान के अनुसार में दृष्टि का वर्णन करता हूँ।
- दृष्टि विशारदों का मानना है कि नेत्र बुदबुद के आयाम का एक-तिहाई भाग कृष्ण मण्डल होता है तथा कृष्णमण्डल के सातवें भाग के बराबर प्रमाण की दृष्टि है।

डल्हन टीका - इदानीं तस्मिन्नेत्रबुदबुदे यददृष्टिमण्डलं तस्य प्रमाणं पूर्वाचार्यप्रतिपादितप्रमाणानुरूपं प्रतिपादयितुमाह-दृष्टिं चेत्यादि। विशारदो विदेहः। कृष्णात् सप्तममिति कृष्णमण्डलात् सप्तमं भागं दृष्टिमिच्छन्ति। दृष्टिविशारदाः शालाकिनः। एतत् प्रमाणं परमतमव्यप्रतिषिद्धत्वादानुमतमेव। तस्य सप्तमांशस्य किं प्रमाणस्यादिति कथनाय मसूरदलमात्रमित्यग्रे निर्देशः; अथवा शालाकिनां परमतमभिधाय मसूरदलमात्रमिति स्वमतमभिधास्यत्याचार्यः। यद्येवं तदहर्थातुरोपक्रमणीय 'नवमस्तारकांशो दृष्टिः' इति कथमुक्तवान्? सत्यं महापुरुषाणां पूर्णायुषां भिन्नविषयमभिधानमिति न दोषः। अतोऽन्यान्यपि समाधानानि पंचिको सन्ति, तानि विस्तरभयान्न लिखतानि। केचिदिमं पाठमन्यथा कृत्वाऽऽपातनिकापूर्वकं पठन्ति, स चाभावान्न लिखतः ॥

दृष्टि विमर्श-

“मसूरदलमात्रं तु पञ्चभूतप्रसादजाम्।

खद्योतविस्फुलिङ्गाभमिद्धां तेजोभिरव्ययैः।

आवृतां पटलेनाक्ष्णोर्बाह्येन विवराकृतिम्।

शीतसात्म्यां नृणां दृष्टिमाहुर्नयनचिन्तकाः ॥” सु.उ. 7/3-4 (दृष्टिरोगविज्ञानीयमध्याय)

- दृष्टि मसूरदल के समान आकृति की है तथा पञ्चमहाभूतों के प्रसाद भाग से बनी होती है।
- खद्योत (जुगनू) तथा अग्निकर्ण के समान आभा चमक वाली। दृष्टि अव्यय नाशरहित तेज से व्याप्त होती है।
- दृष्टि बाहर से नेत्रगोलक के कई पटलों से आवृत किन्तु बाहर से देखने पर विवर (खाली स्थान) के स्वरूप की होती है। शीत आहार-विहार दृष्टि के लिए सात्म्य होता है।

विमर्श-

आचार्य सुभुत ने सूत्र स्थान अध्याय 35 (आतुरोपक्रमणीय अध्याय) में दृष्टि को तारका का नवम् भाग कहा है यथा -

“नयनत्रिभागपरिणाहा तारका, नवमस्तारकांशो दृष्टिः।”

डल्हन टीका - नयनेत्यादि नयनत्रिभागोद्वियवप्रमाणः, तत्परिणाहा तारका कृष्णभाग इत्यर्थः। नवमेत्यादि तारकानवमांशो दृष्टि मण्डलं शल्यतन्त्राभिहितप्रमाणं, शालाक्यतन्त्रप्रमाणं तु मसूरदल मात्रमेव, अतो न दोषः, अथवा तारकानवांशेनापि मसूर दलमात्रमेव भवति, तारका शब्देनात्रापि कृष्णविभागः। “केशान्तेत्यादि केशान्त.....।।

जबकि उत्तरतंत्र-अध्याय 1 में दृष्टि को कृष्णभाग का सप्तमांश स्वीकार किया गया है। आचार्य डल्हन ने इस शंका का निवारण करते हुए कहा है कि महापुरुषों व पूर्णायु का भोग करने वाले व्यक्तियों की विशेषतावश यह भिन्नता होती है।

मण्डल, सन्धि व पटल विमर्श

“मण्डलानि च सन्धीश्च पटलानि च लोचने।

यथा क्रमं विजानीयात् पञ्च षट् च षडेव च।। सु.उ. 1/14

o नेत्र में मण्डल, सन्धियों और पटल क्रम से 5, 6 और 6 होते हैं।

डल्हन टीका-इदानीं नयनस्थ रोगाधिष्ठान कथनाय मण्डलादिसंख्या माहमण्डलानीत्यादि। केचिदेवं पठन्ति - “लोचने मण्डलान्यन्तान् सन्धीश्च पटलानि च। जानीयात् क्रमशः पञ्च चतुरः षट् षडेव च” - इति। एष पाठो निबन्धकारैर्दूषितः।।

मण्डल :

पक्ष्मवर्त्मश्वेतकृष्णदृष्टीनां मण्डलानि तु।

अनुपूर्वन्तु ते मध्याश्चत्वारोऽन्त्या यथोत्तरम्।।” (सु.उ. 1/15)

नेत्र में पक्ष्म, वर्त्म, श्वेत, कृष्ण व दृष्टि ये पांच मण्डल होते हैं जैसे पक्ष्म मण्डल, वर्त्ममण्डल, श्वेतमण्डल, कृष्णमण्डल व दृष्टिमण्डल। उनमें से चार (वर्त्म, श्वेत, कृष्ण तथा दृष्टि) मण्डल पूर्व क्रम से अन्त की तरफ होते हैं। अर्थात् सबसे बाहर वर्त्ममण्डल, उसके भीतर श्वेतमण्डल फिर उसके भीतर कृष्ण मण्डल तत्पश्चात् उसके भीतर दृष्टिमण्डल सबसे अंत में स्थित होता है।

सन्धि :

“पक्ष्मवर्त्मगतः सन्धिर्वर्त्मशुक्लगतोऽपरः।

शुक्लकृष्णगतस्त्वन्यः कृष्णदृष्टिगतोऽपरः।

ततः कनीनकगतः षष्ठश्चापाङ्गः स्मृतः। सु.उ. 1/16

सन्धियों 6 होती हैं जैसे - (1) पक्ष्म तथा वर्त्म की सन्धि, (2) वर्त्म और शुक्ल की सन्धि, (3) शुक्ल और कृष्णभाग की सन्धि (4) कृष्ण और दृष्टि की सन्धि, (5) कनीनक सन्धि, (6) अपांग सन्धि

पटल :

द्वे वर्त्मपटले विद्याञ्चत्वार्यन्यानि चाक्षिणि।

जायते तिमिरं येषु व्याधिः परमदारुणः।।

तेजोजलाश्रितं बाह्यं तेष्वन्यत् पिशिताश्रितम्।

मेदस्तृतीयं पटलमाश्रितन्वस्थि चापरम्।।

पंचमांशसमं दृष्टेस्तेषां बाहुल्मिष्यते। सु.उ. 1/17-18

- o नेत्र में छः पटल होते हैं जिनमें दो पटल वर्त्मपटल नेत्र के बाहर होते हैं व चार पटल नेत्र के अन्तस्थ होते हैं।
- o इन्हीं नेत्र गोलक के अन्तस्थ चार पटलों में अत्यन्त दारुण तिमिर नामक रोग होता है।
- o इन चार पटलों में प्रथम बाह्य पटल तेज व जल के आश्रित होता है, दूसरा पटल मांस के आश्रित है, तृतीय पटल मेद के आश्रित तथा चतुर्थ व अन्तिम अस्थि के आश्रित होता है। इन चारों पटलों की मोटाई दृष्टि के पांचवे भाग के बराबर प्रमाण की है।

डल्हन टीका - पटलान्याह - द्वे इत्यादि। चत्वार्यन्यानि चाक्षिणि अपराण्यपि चत्वारि पटलान्यक्षिणि विद्यात्। येषु चतुर्षु पटलेषु इदानीं तान्येव तिमिर स्याश्रयभूतानि चत्वारि पटलानि चिकित्सार्थं विभज्जनाह - तेज इत्यादि। अत्र तेजः शब्देनालोचकतेजः समाश्रयं सिरागतं रक्तबोद्धव्यम्। जलत्वंगगतो रस धातुः बाह्यम अक्षिगोलकस्य प्रथमं पटलं; अन्यत् द्वितीयं, बाहुल्यं स्थूलता।।

नेत्र निर्माण सहायक अवयवः

“सिराणां कण्डराणां च मेदसः कालकस्य च।

गुणाःकालात् परःश्लेष्मा बन्धनेऽङ्गोः सिरायुतः।।” सु.उ. 1/19

- सिरा से लेकर कालकारिथ पर्यन्त अर्थात् सिराओं, कण्डराओं, मेद तथा कालकास्थि जो क्रम से उत्कृष्ट गुण हैं वे ही दोनों नेत्र कण्डरा में सहयोगी होते हैं।
- कालकास्थि के निकट स्थित श्लेष्मा भी सिराओं से युक्त होकर दोनों नेत्रों को बांधने में सहकारी होता है।

नेत्ररोग सामान्य निदान/हेतु

“उष्णाभितप्तस्य जलप्रवेशाद् दूरेक्षणात् स्वप्नविपर्ययांच।

प्रसक्तसंरोदनकोपशोकक्लेशामिघातादतिमैथुनाञ्च।।

शुक्तारनालम्लकुलत्थमाषनिषेवणाद्देगविनिग्रहांच।

स्वेदादथो घूमनिषेवणाञ्च छर्द्विघाताद्दमनातियोगात्।

वाष्पग्रहात् सूक्ष्मनिरीक्षणाञ्च नेत्रेविकाराञ्जनयन्ति दोषाः।।” सु.उ. 1/26-27

- धूप में तापित मनुष्य का अकस्मात् शीतल जल में प्रवेश, दूर की वस्तुओं को अधिक देखना।
- शयन में विषमता (दिन में सोना व रात्रि जागरण)।
- निरन्तर रुदन, कोप, शोक, क्लेश, अभिघात व अति स्त्रीसंभोग से। शुक्त (सिरका), आरनाल (काज्जी), अम्लपदार्थ, कुलथी, उड़द का अत्यधिक सेवन करने से।
- मलमूत्रादि अधारणीय वेगों के धारण से। अधिक पसीना आने से। अधिक धूम्रपान करने से। वमन के वेग को रोकने से। वाष्प (अश्रु) को रोकने से, सूक्ष्म वस्तुओं को अधिक देखना → वात प्रकुपित होकर नेत्र रोगों की उत्पत्ति।

अष्टांगहृदयानुसार :

“सर्वरोगनिदानोक्तैरहितैः कुपिता मलाः।

अचक्षुष्यैर्विशेषेण प्रायः पित्तानुसारिणः।।

शिरामिरुर्ध्वं प्रसृता नेत्रावयवमाश्रिताः।

वर्त्म सन्धिं सितं कृष्णं दृष्टिं वा सर्वमक्षि वा।। रोगान् कुर्युः।

निदानस्थान के सर्वरोगनिदानाध्याय में वर्णित विशेषतः नेत्रदोषों को प्रकुपित करने वाले आहार-विहार का सेवन करने से पित्त प्रधान दोष नेत्र संबंधी शिराओं द्वारा उर्ध्वगमन नेत्रावयवों में स्थान संश्रय → वर्त्म, नेत्रसंधि, श्वेतभाग, कृष्णभाग, दृष्टिभाग अथवा सम्पूर्ण नेत्र रोगोत्पत्ति।

नेत्र रोग सम्प्राप्ति

“सिराऽनुसारिभिर्दोषैर्विगुणैरूर्ध्वमागतैः।

जायन्ते नेत्रमागेषु रोगाः परमदारुणाः।।” सु.उ. 1/20

मिथ्या आहार-विहार से वातादि दोष विकृत होकर सिराओं का अनुसरण कर शरीर के उर्ध्व भाग में स्थित होकर नेत्रगोलक के विभिन्न भागों में अत्यन्त दारुण रोग उत्पन्न होते हैं।

उल्लेख टीका— इदानीं नेत्र रोगाणां सामान्यां सम्प्राप्तिमाह — सिरानुसारिभिरित्यादि। सिरा अत्र नेत्रगताः। विगुणैः प्रकुपितैः। नेत्रमागेषु नेत्रावयवेषु। नेत्रराजिष्विति केचित् पठन्तिः तत्र नेत्राण्येव राजयो नेत्रराजयः।

नेत्र रोग पूर्वरूप

“तत्राविलं संसंरम्भमश्रुकण्डूपदेहवत्।

गुरुषातोदरागाद्यैर्जुष्टञ्चाव्यक्तलक्षणैः।

सशूलं वर्त्मकोषेषु शुकपूर्णाभमेव च।

विहन्यमानं रूपे वा क्रियास्वक्षि यथा पुरा।।

दृष्ट्वैव धीमान् बुध्येत दोषेणाधिष्ठितं तु तत्।।” सु.उ. 1/21-23

- नेत्रों में अविलता (मैलापल), संरम्भ (रक्ताधिक्य) तथा निरन्तर अश्रुस्राव। कण्डू व स्राव पश्चात् पक्ष्मों का चिपकना।

- कफप्रकोप से गुरुता , पित्त प्रकोप से दहन समान प्रतीती , वातप्रकोप से तोद एवं रक्तप्रकोप से रागता ये लक्षण अल्प मात्रा में प्रकट होना।
- वर्म के कोष में शूल तथा उनका शूक भरे हुए जैसा प्रतीत होना। दर्शन व प्रकाश असह्यता व अबलोकनादि क्रियाएं भी बाधित प्रतीत होना।।
- इस तरह बुद्धिमान वैद्य इन पूर्वरूपों का सम्यक ज्ञान होना चाहिए व आगामी नेत्ररोगों को इंगित करने वाले लक्षण समझने चाहिए।


नेत्र रोग सामान्य चिकित्सा-

“संक्षेपतः क्रियायोगो निदान परिवर्जनम्।

वातादीनां प्रतीघातः प्रोक्तो विस्तरतः पुनः।।” सु.उ. 1/25

- संक्षेप में निदान परिवर्जन अर्थात् जिन कारणों से नेत्र रोग उत्पन्न होते हैं उनका त्याग करना ही क्रियायोग (चिकित्सा) है।
- तत्पश्चात् वातादि दोषों का प्रतिघात (विषमता को समता) करना यह दूसरा उपचार है।

इल्हण टीका - किं तदभिषग्जितं पूर्वरूपे कुर्यादित्याशङ्क्य संक्षेपविस्ताराम्भ्यां तत्रभिषग्जितमाह संक्षेपत इत्यादि। क्रियाणां संशमन संशोधननादीनामयमेव सम्यग्योगः। किं तदित्याह-निदान परिवर्जनमिति। निदानानां दोषकारकहेतूनां रोगकारकहेतूनां च सर्वतो वर्जनम्। विस्तरेण पुनर्वातादीनां प्रतीघातःक्रियोयोगः प्रोक्तः। येनोषधप्रयोगेण वातादीनां कोपः प्रतिहन्यते स उपक्रम उक्त इत्यर्थः।”

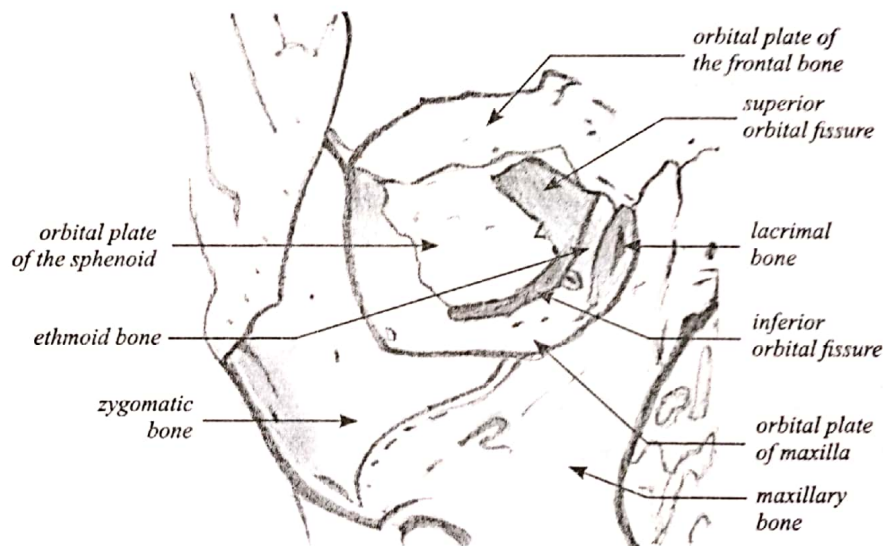


Anatomy of the eyeball

- The human eye is a complex anatomical device that remarkably demonstrates the architectural wonders of the human body. Like a camera, the eye is able to refract light and produce a focused image that can stimulate neural responses and enable the ability to see.

Orbital cavity:

- The roof: **frontal bone**. Posteriorly, the lesser wing of the **sphenoid bone** containing the optic canal completes the roof.
- The lacrimal gland is located in the lacrimal fossa in the anterior lateral aspect of the roof.
- The lateral wall is separated from the roof by the superior orbital fissure, which divides the lesser from the greater wing of the **sphenoid bone**. The anterior portion of the lateral wall is formed by the orbital surface of the **zygomatic (malar) bone**. This is the strongest part of the bony orbit.
- The orbital floor is separated from the lateral wall by the inferior orbital fissure. The orbital plate of the **maxilla** forms the large central area of the floor and is the region where blowout fractures most frequently occur. The frontal process of the maxilla medially and the **zygomatic bone** laterally complete the inferior orbital rim. The orbital process of the **palatine bone** forms a small triangular area in the posterior floor.

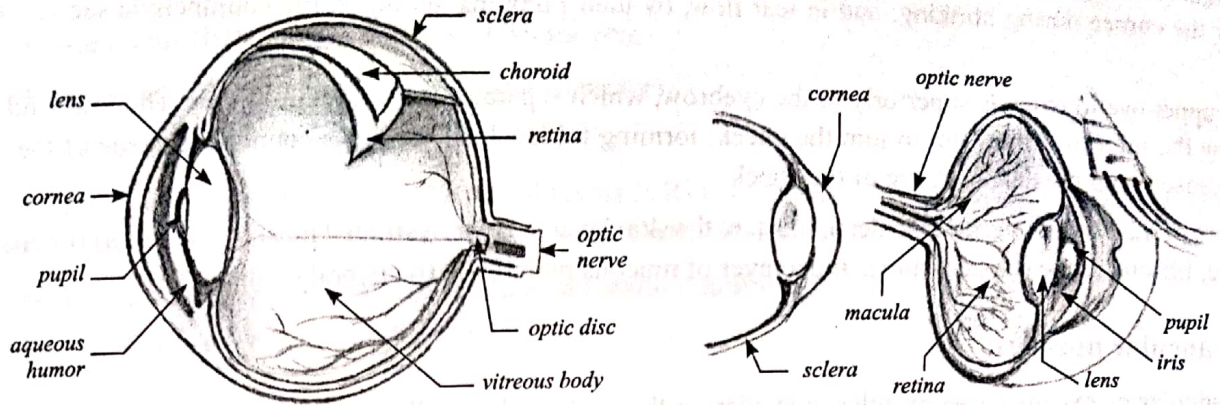


Medial wall: ethmoid bone; lacrimal bone; The body of the **sphenoid** (most posterior aspect of the medial wall) **frontal bone** forms the upper part of the posterior

- lacrimal crest. The lower portion of the posterior lacrimal crest is made up of the **lacrimal bone**. The anterior lacrimal crest is easily palpated through the lid and is composed of the frontal process of the **maxilla**. The lacrimal groove lies between the two crests and contains the lacrimal sac
- Orbital apex:** entry portal for all nerves and vessels to the eye and the site of origin of all extraocular muscles except the inferior oblique.
- The superior ophthalmic vein and the lacrimal, frontal, and trochlear nerves pass through the lateral portion of the fissure that lies outside the annulus of Zinn. The superior and inferior divisions of the oculomotor nerve and the abducens and nasociliary nerves pass through the medial portion of the fissure within the annulus of Zinn. The optic nerve and ophthalmic artery pass through the optic canal, which also lies within the annulus of Zinn

Three different layers of the eyeball are:

1. The external layer or fibrous coat: formed by the sclera (posterior 5/6th) and cornea (anterior 1/6th).
2. The intermediate layer/vascular coat: divided into two parts: anterior (iris and ciliary body) and posterior (choroid).
3. The internal layer/nervous coat or the sensory part of the eye, the retina



Dimension of Adult eyeball:

- Horizontal diameter: 23-23.5 mm
- Anteroposterior (AP) diameter: 23.5-24 mm
- Vertical diameter: 23 mm
- Volume: 6.5-6.8 ml

Three chambers of fluid: Anterior chamber (between cornea and iris), Posterior chamber (between iris, zonule fibers and lens) and the Vitreous chamber (between the lens and the retina). The first two chambers are filled with aqueous humor whereas the vitreous chamber is filled with a more viscous fluid, the vitreous humor.

Anatomy of ocular Adenexa

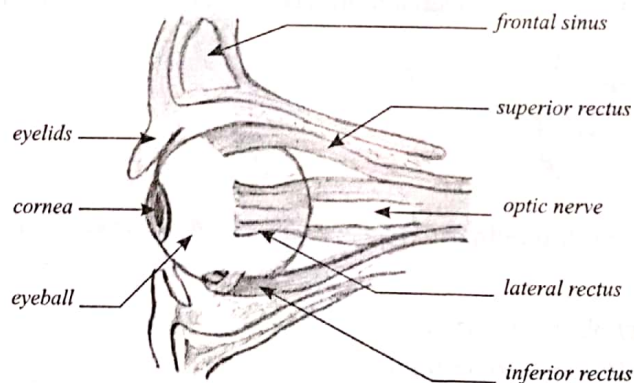
1. Eyelids:

- The eyelids act to protect the anterior surface of the globe from local injury. Additionally, they aid in regulation of light reaching the eye; in tear film maintenance, by distributing the protective and optically important tear film over the cornea during blinking; and in tear flow, by their pumping action on the conjunctival sac and lacrimal sac.
- The upper eyelid extends superiorly to the eyebrow, which separates it from the forehead. The lower lid extends below the inferior orbital rim to join the cheek, forming folds where the loose connective tissue of the eyelid is juxtaposed with the denser tissue of the cheek.
- Layers of lid: From superficial to deep, they are the skin layer, a layer of striated muscle (orbicularis oculi), areolar tissue, fibrous tissue (tarsal plates), and a layer of mucous membrane (palpebral conjunctiva).

2. Extraocular muscles:

Extraocular or extrinsic eye muscles, considering their relatively small size, are incredibly strong and efficient. There are the six extraocular muscles, which act to turn or rotate an eye about its vertical, horizontal, and antero-posterior axes:

1. Medial rectus (MR)
2. Lateral rectus (LR)
3. Superior rectus (SR)
4. Inferior rectus (IR)
5. Superior oblique (SO)
6. Inferior oblique (IO)



- The primary muscle that moves an eye in a given direction is known as the "agonist". a muscle in the same eye that moves the eye in the same direction as the agonist is known as a "synergist," while the muscle in the same eye that moves the eye in the opposite direction of the agonist is the "antagonist." according to "Sherrington's Law", increased innervations to any agonist muscle are accompanied by a corresponding decrease in innervation to its antagonist muscle(s).

Nerve supply:

Each extraocular muscle is innervated by a specific cranial nerve (C.N.):

1. Superior oblique (SO)—cranial nerve IV (Trochlear)
2. Inferior oblique (IO)—cranial nerve III (Oculomotor)
3. Superior rectus (SR)—cranial nerve III (Oculomotor)
4. Inferior rectus (IR)—cranial nerve III (Oculomotor)
5. Medial rectus (MR)—cranial nerve III (Oculomotor)
6. Lateral rectus (LR)—cranial nerve VI (abducens)

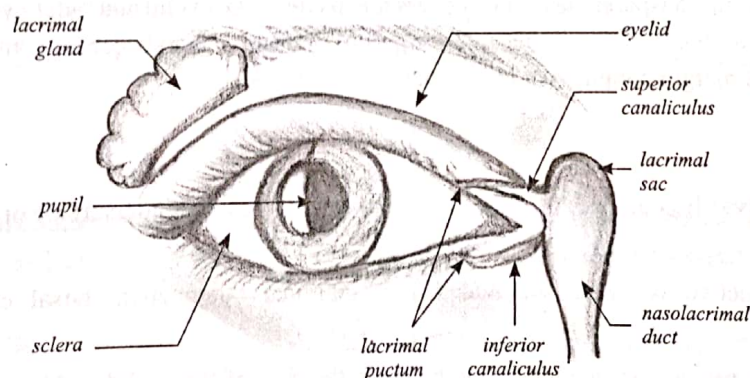
Pneumonic: LR6 (SO4) 3 - That is, the lateral rectus (LR) is innervated by C.N. 6, the superior oblique (SO) is innervated by C.N. 4, and the four remaining muscles (MR, SR, IR, and IO) are innervated by C.N. 3.

Anatomy of lacrimal apparatus: The lacrimal apparatus comprises

1. Main lacrimal gland
2. Accessory lacrimal glands
3. Lacrimal passages, which include: puncta, canaliculi, lacrimal sac and nasolacrimal duct (NLD).

1. Main lacrimal gland: It consists of an upper orbital and a lower palpebral part.

- a. **Orbital part:** Orbital part is larger, about the size and shape of a small almond, and is situated in the fossa for lacrimal gland at the outer part of the orbital plate of frontal bone. It has got two surfaces — superior and inferior. The superior surface is convex and lies in contact with the bone. The inferior surface is concave and lies on the levator palpebral superioris muscle.
- b. **Palpebral part:** Palpebral part is small and consists of only one or two lobules. It is situated upon the course of the ducts of orbital part from which it is separated by LPS muscle. Posteriorly, it is continuous with the orbital part.
- c. **Ducts of lacrimal gland.** Some 10-12 ducts pass downward from the main gland to open in the lateral part of superior fornix. One or two ducts also open in the lateral part of inferior fornix.



2. Accessory lacrimal glands:

- a. **Glands of Krause:** These are microscopic glands lying beneath the palpebral conjunctiva between fornix and the edge of tarsus. These are about 42 in the upper fornix and 6-8 in the lower fornix.
- b. **Glands of Wolfring:** These are present near the upper border of the superior tarsal plate and along the lower border of inferior tarsus. All lacrimal glands are serous acini, similar in structure to the salivary glands. Microscopically these consist of glandular tissue (acini and ducts), connective tissue and puncta.

Blood supply: Main lacrimal gland is supplied by lacrimal artery which is a branch of ophthalmic artery.

Nerve supply:

- a. Sensory supply comes from lacrimal nerve, a branch of the ophthalmic division of the fifth nerve.
- b. Sympathetic supply comes from the carotid plexus of the cervical sympathetic chain.
- c. Secretomotor fibres are derived from the superior salivary nucleus.

3. Lacrimal passages:

- a. **Lacrimal puncta:** These are two small, rounded or oval openings on upper and lower lids, about 6 and 6.5 mm, respectively, temporal to the inner canthus. Each punctum is situated upon a slight elevation called lacrimal papilla which becomes prominent in old age.
- b. **Lacrimal canaliculi:** These join the puncta to the lacrimal sac. Each canaliculus has two parts: vertical (1-2 mm) and horizontal (6-8 mm) which lie at right angle to each other. The horizontal part converges towards inner canthus to open in the sac. The two canaliculi may open separately or may join to form common canaliculus which opens immediately into the outer wall of lacrimal sac. A fold of mucosa at this point forms the valve of Rosenmuller which prevents reflux of tears.
- c. **Lacrimal sac:** It lies in the lacrimal fossa located in the anterior part of medial orbital wall. The lacrimal fossa is formed by lacrimal bone and frontal process of maxilla. It is bounded by anterior and posterior lacrimal crests. When distended, lacrimal sac is about 15 mm in length and 5-6 mm in breadth. It has got three parts: fundus (portion above the opening of canaliculi), body (middle part) and the neck (lower small part which is narrow and continuous with the nasolacrimal duct).
- d. **Nasolacrimal duct (NLD):** It extends from neck of the lacrimal sac to inferior meatus of the nose. It is about 15-18 mm long and lies in a bony canal formed by the maxilla and the inferior turbinate. Direction of the NLD is downwards, backwards and laterally. Externally its location is represented by a line joining inner canthus to the ala of nose. The upper end of the NLD is the narrowest part. There are numerous membranous valves in the NLD, the most important is the valve of Hasner, which is present at the lower end of the duct and prevents reflux from the nose.

Anatomy of conjunctiva:

- The conjunctiva is a thin transparent layer that covers the inside of the eyelid and outer eye. It covers the posterior surface of the lids and reflects to cover the anterior part of the sclera, then becomes continuous with the corneal epithelium. At the lid margin conjunctiva is continuous with the skin.

Types of conjunctiva:

1. **Palpebral conjunctiva:** It is the part of the conjunctiva which lines the undersurface or posterior surface of the eyelid.
 - a. Palpebral conjunctiva is again subdivided into marginal conjunctiva, tarsal conjunctiva and orbital conjunctiva.
 - b. Marginal conjunctiva is a transitional zone between the skin of the eyelid and conjunctiva proper. It starts from the intermarginal strips of the eyelid as a continuation of the skin. It is made up of stratified epithelium. Marginal conjunctiva continues in to the back or posterior surface of the lid for a short distance of 2 mm, up to a shallow groove or fold, where it merges with the conjunctiva proper. This groove is called sub tarsal sulcus or sulcus subtarsalis.
 - c. Orbital conjunctiva is loosely covering between the tarsal plate and fornix. It is thrown in to horizontal folds during eye movements. In upper eyelid it lies over the Muller's muscle.

2. **Bulbar conjunctiva:** It is the thinnest of all the parts of conjunctiva and so transparent that underlying white sclera and vessels are seen clearly. It is loosely attached except for a zone of 3mm near the limbus and near insertions of the recti muscles. Limbal conjunctiva is the part of the bulbar conjunctiva which covers the limbal region and fuses with the corneal epithelium
3. **Fornicial conjunctiva:** it is fold lining the cul-de-sac formed by conjunctiva covering the posterior surface of the lids to the conjunctiva covering the anterior surface of the globe. The conjunctiva here is comparatively thicker and loosely attached in order to allow free movement of the globe. It is divided into 4 regions
 - a. Superior fornix
 - b. Inferior fornix
 - c. Lateral fornix
 - d. Medial fornix
 - The conjunctiva extends from the corneoscleral limbus to the mucocutaneous junction on the eyelids. The conjunctiva reflects to form a fornix on three sides and an extendible plica medially. The redundant conjunctiva in this region allows for independent movement of the eye and eyelids. Conjunctival surface folds increase the surface area of the conjunctiva, decrease the area of contact, and reduce friction between the bulbar and tarsal conjunctiva.
 - The conjunctival surface is composed of stratified nonkeratinizing epithelium and varies in thickness and appearance from the eyelid margin to the limbus. Unlike any other stratified squamous epithelium, goblet cells are dispersed among and attached to neighboring epithelial cell.

Histology/layers of conjunctiva:

1. **Conjunctival Epithelium:** at the junctions of skin of the lids and marginal conjunctiva (mucocutaneous junction), keratinised squamous epithelium of the epidermis transforms into nonkeratinised squamous epithelium of conjunctiva. Morphology of conjunctival epithelium varies from region to region.
2. **Substantia propria or conjunctival sub mucosa:** It consists of superficial lymphoid layer and deeper fibrous layer. The conjunctival epithelium rests on a connective tissue layer called the substantia propria. Numerous mast cells (6000/mm³), lymphocytes, plasma cells, and neutrophils are normally present in this layer
3. **Fibrous layer:** This layer contains the vessels and nerves of conjunctiva and glands of Krause. Except for the tarsal part of conjunctiva, where it is very thin and blends with the tarsal plates, the fibrous layer is thicker than the lymphoid layer.

Anatomy of sclera

The term sclera is derived from Greek word 'Scleros' meaning "hard". Sclera is an opaque, elastic, and resilient tissue of the eye. It can be compared with an incomplete shell comprising approximately 90% (five-sixths) of the outer coat of the eye.

- Anteriorly it begins at the limbus and terminates at the optic nerve canal posteriorly. The primary function of the sclera is to protect the eye and maintain the shape of the eye ball.
- The human sclera is white in colour. This white appearance is because of the scattering of all wavelengths of light by dense irregular bundles of collagen in sclera. In children, a bluish hue is observed because of the extremely thin sclera which allows the visibility of underlying choroid. In older age the sclera may appear slightly yellowish because of the deposition of fat.

- Sclera is thicker in males than in females. Human sclera is thickest near the optic nerve, where it is approximately 1 mm in thickness and thinnest at the insertion of extra ocular muscles (0.3 mm). Sclera gradually thickens towards cornea and at limbus the thickness of sclera is 0.83 mm.

Layers of sclera:

1. **Episclera:** The episclera is the thin densely vascularized layer of connective tissue overlying the sclera and situated below the tenon's capsule. Apart from the vessels and unmyelinated nerve fibres, it contains bundles of collagen and also cells like fibroblast and occasional melanocytes. Anteriorly episclera blends with Subconjunctival tissues and tenon's capsule 1 to 3 mm behind the limbus. It becomes very thin and indistinct posterior to the equator.
2. **Sclera proper:** sclera proper or scleral stroma is also called substantia propria. Ultrastructurally, sclera is composed of collagen bundles, elastic fibres, fibroblasts and ground substances. These ground substances are proteoglycans and glycoproteins. Collagen bundles in sclera are of varying sizes and are irregularly arranged the reason why sclera is not transparent like cornea. This variation in scleral collagen fibres are more marked in mid-sclera, where the diameter of the fibres range from 50 to 400 nm. The scleral fibroblasts play an important role in synthesis and organization of collagen, proteoglycans and glycoproteins.
3. **Lamina Fusca:** Lamina fusca is the innermost layer of sclera. It is characterised by abundance of pigmented cells or melanocytes, mostly migrated from choroid. The connective tissue of this layer is loosely arranged than rest of the sclera. Lamina fusca is separated from choroid by a thin potential space known as suprachoroidal or perichoroidal space.

Anatomy of cornea:

One-sixth of the outer layer of the eye (called the tunic fibrosa or fibrous tunic) bulges forward as the cornea, the transparent dome which serves as the outer window of the eye.

- The cornea is the primary (most powerful) structure focusing light entering the eye (along with the secondary focusing structure, the crystalline lens)
- The cornea is the transparent front part of the eye that covers the iris, pupil, and anterior chamber. Together with the lens, the cornea refracts light, accounting for approximately two-thirds of the eye's total optical power. In humans, the refractive power of the cornea is approximately 43 dioptres.
- The cornea has unmyelinated nerve endings sensitive to touch, temperature and chemicals; a touch of the cornea causes an involuntary reflex to close the eyelid. Because transparency is of prime importance the cornea does not have blood vessels; it receives nutrients via diffusion from the tear fluid at the outside and the aqueous humour at the inside and also from neurotrophins supplied by nerve fibres that innervate it.
- In humans, the cornea has a diameter of about 11.5 mm and a thickness of 500-600 μm in the center and 600-800 μm at the periphery. Transparency, avascularity, the presence of immature resident immune cells, and immunologic privilege makes the cornea a very special tissue.
- The corneal shape is maintained by its elastic properties in conjunction with intraocular pressure (10-21 mm Hg) generated by the continuous production and outflow of aqueous humor in the eye

Layers of cornea:

1. **Corneal epithelium:** Epithelium represents 10 percent of the corneal thickness. Corneal epithelium is a stratified squamous nonkeratinised epithelium.
2. **Bowman's layer:** acellular tough membrane like zone situated in between corneal epithelium and stroma. It is 8-14 μm thick and composed of randomly arranged collagen fibers. Though the collagen fibers are finer than those found in corneal stroma and randomly arranged, these collagen fibers are continuous with that of anterior stroma.

Because of the compact arrangement of collagen fibers, it is comparatively resistant to trauma. However, once destroyed it cannot be regenerated.

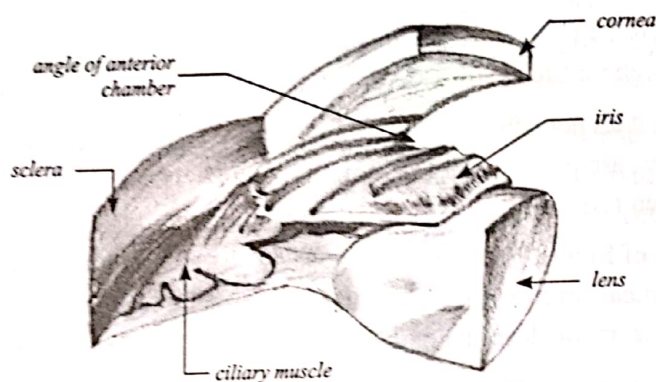
3. **Corneal stroma:** Stroma or substantia propria, which occupies about 90% of the total corneal thickness, is composed of collagen fibrils, keratocytes and extracellular ground substances. Collagen components constitute more than 70% of the dry weight of cornea. Collagen fibrils with uniform 25 to 35-nm diameter are arranged in flat bundles called lamellae. The lamellae extend from limbus to limbus and are oriented at various angles to one another. Collagen fibers form approximately 300 lamellae in corneal stroma. Two properties of corneal collagen fibers, which accounts for the transparency of cornea, are-
 - a. Collagen fibers are highly uniform in diameter (25-35 nm)
 - b. The distance between two corneal fibers is also highly uniform (41.5nm). Corneal transparency is mainly dependent on the arrangement of these collagen fibers in stroma.
4. **Descemet's membrane:**
 - a. Descemet's membrane is the thick basement membrane secreted by the endothelium. It is produced constantly and so it thickens throughout life (3 μm at birth and increases to 10 μm in adult).
 - b. Descemet's membrane does not adhere strongly to the stroma, and so, it can be surgically dissected as a sheet. Though no elastic fibers are present, the Descemet's membrane exhibit elastic property due to the particular arrangement of collagen fibers.
 - c. Unlike the attachment of Bowman's membrane and corneal stroma, Descemet's membrane is comparatively weakly attached to corneal stroma and this surface is sharply defined. Descemet's membrane is a tough layer which is resistant to enzymatic degradation by phagocytes and toxins.
5. **Corneal endothelium:** corneal endothelium is a simple squamous epithelium. The shape of the individual cells is hexagonal which forms continuous mosaic pattern, best seen in microscopy. These cells possess ion transport system which is known as endothelial pump. These endothelial pumps regulate the water content of corneal stroma

Anatomy of Anterior chamber:

- Anterior chamber is an angular space bounded anteriorly by the posterior (inner) surface of the cornea and posteriorly by the anterior surface of the iris and a part of ciliary body. Anterior chamber is 3 mm deep and it contains 0.25 ml of the aqueous humour. Anterior chamber depth is shallower in the hypermetropic eye than the myopic eye. It is also shallower in children and in older people.
- **Boundaries of anterior chamber:**
 - a. Anteriorly:
 1. Inner surface of the cornea
 2. at periphery, trabecular meshwork
 - b. Posteriorly:
 1. Lens
 2. Anterior surface of the iris
 3. Anterior face of the ciliary body.
- Anterior chamber details:
 - a. Volume: 220 μL .
 - b. Chamber Volume decreases by 0.11 μL /year life

- c. Depth: 3.15mm (2.6- 4.4mm)
- d. Chamber depth decreases by 0.01mm/year of life.
- e. Chamber depth is shallower in the hypermetropic than myopic .Chamber deepens by 0.06mm for each diopter of myopia.
- f. Chamber depth is slightly diminished during accommodation, partly by increased lens curvature & partly by forward translocation of the Lens.
- g. Wide angle of anterior chamber denotes the eye in which the angle between iris and surface of the trabecular meshwork is between 20 to 45 degrees. Angles less than 20 degrees are termed as narrow angles

Anatomy of Angle of Anterior chamber



Structures in the anterior chamber: following structures are visible in gonioscopy in normal angle from anterior to posterior:

1. **Schwalbe's line:** formed by collagen condensation of the Descemet's membrane which lies between corneal endothelium and trabecular meshwork. Visible as a thin, translucent line projecting into the anterior chamber.
2. **Trabecular meshwork:** most anterior structure seen in gonioscopy. It has got dull greyish appearance and translucent, it extends upto the scleral spur.
3. **Scleral spur:** it is short extension of the sclera. It appears as white and opaque.
4. **Ciliary body band:** palish grey to brown band, the width of visibility of the ciliary body band depends upon the iris insertion.

Anatomy of uveal tract:

- Uvea is the middle vascular coat of eye ball. From anterior to posterior, the uvea or uveal tract can be divided into three parts- Iris, Ciliary body and choroid. The name "uvea" has originated from Latin word which means 'grape'.

A. Iris:

- a. Iris is the anterior most part of the uveal tract. It is a thin and circular structure which forms a diaphragm like structure in front of the crystalline lens. The diaphragm formed by iris contains a central aperture known as pupil. The location of the pupil is not exactly central, its little nasal to the center.
- b. The pupil determines the amount of light entering the eye. The normal size of pupillary aperture is 3-4 mm.
- c. Iris is attached to the middle of anterior surface of ciliary body. The iris divides the space in front of the lens into anterior chamber and posterior chamber. Average diameter of the iris is 10 to 11 mm. It is thickest at

collarette, which is located approximately 1.5 mm from the pupillary margin and thinnest at iris root, the part of iris which joins with the ciliary body. The thickness of iris root is approximately 0.5 mm.

- d. Anterior surface of the iris is divided into a pupillary zone and a ciliary zone by a circular ridge, located 1.5 mm away from pupillary margin, called collarette (also known as iris frill).
- e. Pupillary zone of iris: extends from pupillary margin to collarette. Pupillary zone is relatively flat. Pupillary margin is marked by a dark border, known as pupillary ruff. Pupillary ruff is the anterior termination of the pigmented layer, which lines the posterior surface of iris.
- f. Ciliary Zone of iris: Ciliary zone of iris extends from collarette to iris root. There are some depressions or pits arranged in rows present in this area known as crypts.

Crypts are found in two locations. Those present near collarette are relatively larger and known as Fuchs's crypt and few are seen in periphery of the iris.

Layers of iris:

1. **Anterior limiting layer:** anterior limiting layer lines the iris and is the anterior most condensations of iris stroma. The layer consists of mainly fibroblasts and melanocytes. These cells are arranged in a meshwork-fibroblasts are located on the surface and melanocyte beneath them.
2. **Iris stroma:** Iris stroma forms the main bulk of iris tissue and contains sphincter pupillae, dilator pupillae muscles, vessels and nerves. Fibroblasts are the most prominent cells in iris stroma. These cells are located in close association with blood vessels, muscles, and nerves.
3. **Anterior pigment epithelium:** The cells in anterior pigment epithelial layer of the iris have two distinct portions. Muscular basal portion anteriorly (lies next to stroma): composed of elongated, contractile, smooth muscle fibres. These muscle fibers extend into the stroma, forming three to five layers of dilator muscle fibers joined by tight junctions.
4. **Posterior pigment epithelium of iris:** Posterior pigment epithelium is the second layer of pigmented epithelium situated posterior to the iris stroma. The cells are rectangular or pyramidal in shape with round cell nucleus and their cytoplasm contain large pigment granules.

B. Ciliary body:

1. Ciliary body is the middle part of the uveal tract. It is a ring (slightly eccentric) shaped structure which projects posteriorly from the scleral spur, with a meridional width varying from 5.5 to 6.5 mm. It is brown in colour due to melanin pigment. Anteriorly it is confluent with the periphery of the iris (iris root) and anterior part of the ciliary body bounds a part of the anterior chamber angle. Posteriorly ciliary body has a crenated or scalloped periphery, known as ora serrata, where it is continuous with the choroid and retina.
2. Ciliary body, in cross section, is a triangular structure. Outer side of the triangle is attached with the sclera with suprachoroidal space in between. Anterior side of the triangle forms part of the anterior & posterior chamber. In its middle, the iris is attached. The inner side of the triangle is divided into two parts. The anterior part (2 mm) with finger like processes is known as pars plicata (corona ciliaris) and posterior smooth (4 mm) is known as pars plana (orbicularis ciliaris).

C. Choroid:

- a. Choroid is formed of arterioles, venules and a dense fenestrated capillary network and is loosely attached to the sclera. Choroid has a high blood flow and nourishes the deep, outer layers of the retina and may have a role in its temperature homeostasis.
- b. Its basement membrane together with that of the retinal pigment epithelium (RPE) forms the acellular, Bruch's membrane, which acts as a diffusion barrier between the choroid and the retina.

Anatomy of lens:

- The crystalline lens is a unique transparent, biconvex, avascular intraocular structure with slightly more curved posterior surface. The radius of curvature of anterior surface is 10 mm and that of posterior surface is 6 mm.
- The center of the anterior surface is called anterior pole and it is situated 3mm away from the posterior (endothelial) surface of cornea. The center of the posterior surface is called posterior pole. The distance between these poles is measured as lens thickness. The thickness of lens is 3mm at birth, which increases to 6mm in older age. The marginal circumferences of the lens, where anterior and posterior surface meet, are known as equator. Equatorial or lens diameter is generally measured in nasal to temporal dimension. The equatorial diameter of lens is 6.5 mm at birth, which reaches to 9-10 mm in adult life. The equator of the lens is encircled by the ciliary processes of the ciliary body and held in position by zonules laterally.
- The Lens is situated behind the iris and in front of the vitreous. The posterior lens surface is attached to anterior vitreous in a circular fashion by Hyaloideo capsulare (HC) which is also known as Weiger's ligament. It is not a true ligament and strength of the attachment decreases with age.
- The dioptric power of human eye is approximately 58 diopters. The refractive power of crystalline lens is about 15 diopters. Though lens has less refractive power than cornea, it has the ability to change its shape with the help of ciliary muscle, by which it can change its dioptric power, allowing the distant and near vision. However this property changes with age. Lens has a refractive index of 1.39.
- The eye has the capacity to adjust its focus from distance to near objects because of the ability of the lens to change shape, a phenomenon known as '**accommodation**'. The inherent elastic property of the lens allows it to become more or less spherical depending on the amount of tension exerted by the zonular fibers on the lens capsule. Zonular tension is controlled by the action of the parasympathetically innervated ciliary muscle. When ciliary muscles contracts, relaxation of zonular tension occurs. The lens then assumes a more spherical shape, resulting in increased dioptric power which helps to bring nearer objects into focus. Ciliary muscle relaxation causes the zonular tension to increase. As a result, lens flattens, which helps in bringing more distant objects into view.

Lens histology/Structure of lens:

Lens Fibers - long protein fibers that are closely packed and parallel. This arrangement keeps the lens transparent. They make up most of the lens volume and are laid out horizontally, front to back, and concentrically like layers of an onion. There is also water in and around these fibers. They contain no elements that would scatter light, such as cell nucleus or mitochondria.

1. **Lens Epithelium** - a layer of cells on the anterior (front) side of the lens which act like a pump. The lens has no blood vessels but receives nourishment from the aqueous fluid that flows all around it and carries away its waste products. The lens does not need much oxygen, but receives glucose as its main energy source. The epithelial cells distribute fluid, ions and glucose through the entire lens. They also create new fibers throughout a person's life.
2. **Lens Capsule** - a transparent membrane surrounding the lens like a pocket. It is elastic to allow lens curvature to steepen for near vision. When an artificial lens replaces the natural lens in cataract surgery, it is placed in this same capsule.
3. **Nucleus:**
 - a. As lens fibers grow anteriorly and posteriorly, a pattern emerges where the ends of the fibers meet and interdigitate with the ends of fibers arising on the opposite side of the lens, near the anterior and posterior poles. These patterns of cell association are known as sutures. Y-shaped sutures are recognizable at about 6 weeks of gestation, with an erect Y-suture appearing anteriorly and an inverted Y-suture posteriorly.
 - b. As the lens fibers continue to form and the lens continue to grow, the pattern of lens sutures becomes increasingly complex, resulting in 12 or more suture branches in the adult eye.

Zones of lens: approximately nucleus occupies 84% of the lens and cortex occupies 16%. The nucleus is further subdivided into **embryonic, fetal, infantile, and adult nuclei**. The cortex consists of recently formed nucleated fibers which lie outside the adult nucleus of the lens. The fibers of the cortex are loosely arranged whereas fibers of the nucleus are arranged in more compact fashion, the reason for which the nucleus is harder in consistency than cortex.

- c. **Zonules of Lens:** Zonules or suspensory ligament of lens are a group of radially arranged, thread like fibres which helps them to hold in position. Most of the zonules arise from posterior part of pars plana, about 1.5 mm from ora serrata. These fibers run forward in pars plana blending with the basement membrane of the nonpigmented epithelium of pars plana.

Anatomy of vitreous:

- Vitreous is a transparent, colour less gel like structure which occupies the posterior compartment of the eye. It comprises about 80% of the total volume of the globe (two third of total volume of eye), about 4mL. The surfaces of the intraocular structures that interface with vitreous are mainly basement membrane in nature e.g.: pars plana of ciliary body, internal limiting membrane of retina and vitreous is attached to them with varying strength of adhesion.
- **Vitreous attachment:** Vitreous is attached to its surrounding structures by condensation of collagen fibrils. From strongest to weakest, these are-
 - a. Vitreous base-strongest
 - b. Posterior lens capsule with the help of hyaloideocapsular ligament of Weiger
 - c. Margins of the optic disc
 - d. At the macula
 - e. Along the retinal vessels – Most variable and weakest

Anatomy of retina:

- The retina is the innermost layer. It lines the entire posterior portion of the eye with the exception of the area of the optic nerve and extends anteriorly to end 360 degrees circumferentially at the ora serrata. The total area of the retina is approximately 1,100 mm square. The circumferential diameter at the equator of the adult eye averages 69 mm.
- Retinal nerve fibers exit the eye through the optic nerve, located nasally and on the same plane as the anatomical center of the retina. There is no retinal tissue overlying the optic nerve head. The optic nerve head or optic disc is oval in shape and measures approximately 1.75 mm. vertically and 1.5 mm horizontally. The center of the optic disc is located 4.5 mm to 5 mm nasal to the anatomical center of the retina.

The center of the retina provides the greatest resolving power of the eye. This area, responsible for central vision, is known as the **macula**. The center of the macula is called the **fovea**.

- The neuroretina is tightly attached to the underlying retinal pigment only at the margins of the optic nerve and at the ora serrata. There is a potential space between the neurosensory retina and the retinal pigment epithelium. In a retinal detachment, this space fills with fluid and detaches the neurosensory retina from the underlying retinal pigment epithelium.
- Beginning with the innermost layer (closest to the vitreous) and proceeding outwards towards the choroid and sclera, these layers are as follows:
 1. **The inner limiting membrane**
 2. **The nerve fiber layer**

3. The ganglion cells layer
4. The inner plexiform layer
5. The inner nuclear layer
6. The outer plexiform layer
7. The outer nuclear layer
8. The outer limiting membrane
9. The rod and cone layer
10. The pigment epithelium

Vascular Anatomy of eye (Artery):

- The principal arterial supply of the orbit: **ophthalmic artery** (the first major branch of the intracranial portion of the internal carotid artery). This branch passes beneath the optic nerve and accompanies it through the optic canal into the orbit.
- The first intraorbital branch is the **central retinal artery**, which enters the optic nerve. Other branches of the ophthalmic artery include the lacrimal artery, supplying the lacrimal gland and upper eyelid; muscular branches to the various muscles of the orbit; long and short posterior ciliary arteries; medial palpebral arteries to both eyelids and the supraorbital and supratrochlear arteries.
- The short posterior ciliary arteries supply the choroid and parts of the optic nerve. The two long posterior ciliary arteries supply the ciliary body and anastomose with each other and with the anterior ciliary arteries to form the major arterial circle of the iris.
- The anterior ciliary arteries are derived from the muscular branches to the rectus muscles. They supply the anterior sclera, episclera, limbus, and conjunctiva and contribute to the major arterial circle of the iris.
- The most anterior branches of the ophthalmic artery contribute to the formation of the arterial arcades of the eyelids, which make an anastomosis with the external carotid circulation via the facial artery.

Vascular Anatomy of eye (vein):

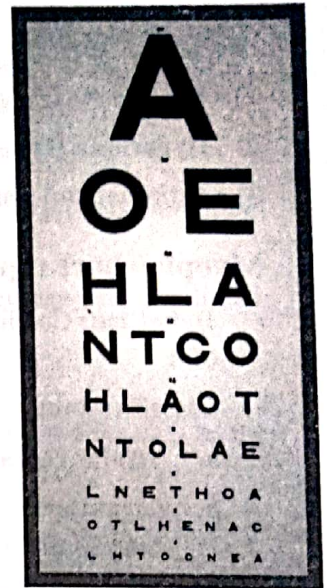- The venous drainage of the orbit is primarily through the superior and inferior ophthalmic veins, into which drain the vortex veins, the anterior ciliary veins, and the central retinal vein.

Examination of the eye:

Testing visual acuity:

The resolving power of the eye used to assess and quantify the eye's ability to resolve varying letter sizes

- Visual acuity is dependent on:
 1. The refractive error of the eye
 2. The health and the integrity of the eye
 3. The test targets used
 4. The test conditions



- **Standard Test Distances:**
 1. Distance visual acuity (DV a): 20ft or 6M is equivalent to optical infinity
 2. Near visual acuity (NV a): 40cms
- **Central visual acuity** refers to the ability of the visual system to discern fine distinctions in the environment as measured with printed or projected visual stimuli. The presence of excellent visual acuity tells the examiner that the ocular media are clear, the image is clearly focused on the retina, the afferent visual pathway is functioning, and the visual cortex has appropriately interpreted signals received. Measurement of visual acuity is a most sensitive test of the integrity of the visual system.
- The goal in testing central visual acuity is to determine the best possible visual acuity in each eye. In most instances, either a standard printed Snellen eye chart is used with the patient 20 feet (6 m) away or a reading card with a reduced eye chart is used at 14 inches (35 cm). One eye at a time is tested with the fellow eye occluded.
- **Snellen's chart:** The symbols on an acuity chart are formally known as "optotypes". In the case of the traditional Snellen chart, the optotypes have the appearance of block letters, and are intended to be seen and read as letters. At 6 meters/20 feet, the letters on the 6/6 line should subtend 5 minutes of arc (such that the limbs of the letters subtend 1 minute of arc). The thickness of the lines equals the thickness of the white spaces between lines and the thickness of the gap in the letter "C" and the height and width of the optotype (letter) is five times the thickness of the line. The letters on the 6/6 line of an eye chart represent a size of print projecting a retinal image subtending a defined arc when viewed at 6 meters (20 feet).
- **Interpretation of Snellen's chart:** 6/6 vision is a term used to express normal visual acuity (the clarity or sharpness of vision) measured at a distance of 6 meters or 20 feet. If you have 6/6 or 20/20 vision, you can see clearly at 6 meters /20 feet what should normally be seen at that distance. If you have 6/60 vision, it means that you must be as close as 6 meters to see what a person with normal vision can see at 60 meters.
- **Near acuity** - the eye's ability to distinguish an object's shape and details clearly at near distances – usually 16 inches (40 cm). various near vision testing charts are used for the acuity testing like:
 1. Snellen's near vision chart
 2. Roman test for near vision
 3. Jaeger's near vision chart
- **Testing colour vision:** The Ishihara Color Test is an example of a color perception test for red-green color deficiencies. The test consists of a number of colored plates, called Ishihara plates, each of which contains a circle of dots appearing randomized in color and size. Within the pattern are dots which form a number or shape clearly visible to those with normal color vision, and invisible, or difficult to see, to those with a red-green color vision defect, or the other way around.
 1. **Achromatopsia:** complete color blindness, seeing only shades of grey
 2. **Deuteranopia:** difficulty in perception of green colour
 3. **Protanopia:** difficulty in perception of red colour
 4. **Tritanopia:** difficulty in perception of blue colour

Refractive errors:

- **Emmetropia :-** when parallel rays of light from a distant object are brought to focus on the retina with the eye at rest "not accommodating".

- **Ametropia** :- when parallel rays of light are not brought to a focus on the retina in an eye at rest. It's simply "refractive error". A change in refraction is needed to achieve sharp vision. Ametropia is divided into:

- 1) **Myopia/Near sightedness**
- 2) **Hyperopia/Hypermertropia/Far sightedness**
- 3) **Astigmatism: non spherical cornea**

1. Myopia/short sightedness:

- **Definition:** Condition of the eye where the light that comes in does not directly focus on the retina but in front of it.
- **Classification:**
 - a. **Axial myopia:** it is attributed to an increase in the eye's axial length.
 - b. **Curvature myopia:** it is attributed to excessive, or increased curvature of one or more of the refractive surfaces of the eye, especially the cornea
 - c. **Index myopia:** it is attributed to variation in the index of refraction of one or more of the ocular media
- **Myopia grading:**
 - a. **Low myopia:** usually describes myopia of 3.00 diopters or less
 - b. **Medium myopia:** usually describes myopia between 3.00 and 6.00 diopters
 - c. **High myopia:** usually describes myopia of 6.00 diopters or more. High myopia is more likely to have retinal detachment and primary open angle glaucoma. They are also more likely to experience floaters, shadow-like shapes which appear singly or in clusters in the field of vision.
- **Ophthalmoscopic findings:** The retina in myopic patients is thin and thorough evaluation of the periphery might show retinal holes and lattice degeneration. In addition, myopic patients might develop choroidal neovascularization in the macula. Macula will have some retinal Pigmentary changes and sometimes will have subretinal hemorrhages.
- **Management of myopia:**
 - a. Prescription of concave lenses (- lens)
 - b. Photorefractive keratectomy.
 - c. Laser-assisted in situ keratomileusis. Commonly called L aSIK, a laser is used to cut a flap through the top of the cornea, a laser removes some corneal tissue, then the flap is dropped back into place. L aSIK is the most common surgery used to correct myopia.

2. Hypermetropia/ Hyperopia / farsightedness/long sightedness

- **Definition:** refractive state of the eye when the parallel rays of light coming from infinity are focused behind the retina given that the accommodation power of the eye is at rest.
- **Types of Hypermetropia:**
 1. **Axial Hypermetropia:**
 - a. Most common type of Hypermetropia
 - b. Total refractive power of the eye is normal
 - c. Axial shortening of the eyeball is the cause
 2. **Index hypermetropia:** the refractive index of the eye is altered as seen in old age.

3. **Curvature hypermetropia:** caused by increased curvature of the cornea and lens
4. **Positional hypermetropia:** change in the lens position in the eyeball (posterior placed lens)
5. **Aphakia** (absence of crystalline lens, most common cause is surgical aphakia)

Clinical classification:

- a. **Simple hypermetropia:** caused by biological variation in the development of eyeball. Axial and curvature hypermetropia are common in this category.
- b. **Pathological hypermetropia:** outside the biological variation, may be a part of aphakia and positional hypermetropia
- c. **Functional hypermetropia:** paralysis of accommodation as in III cranial nerve palsy.

Clinical features: People with Hyperopia can experience blurred vision, asthenopia (tiredness of the eyes as the day progresses), accommodative dysfunction, binocular dysfunction, amblyopia, and strabismus

Management: Prescription of convex lenses (+ lenses) and contact lenses.

3. Astigmatism:

Definition: when light rays aren't refracted uniformly in all meridians due to non spherical shape of cornea or lens, parallel rays passing through these different planes are brought to different points of focus or When parallel rays of light enter the eye (with accommodation relaxed) and do not come to a single point focus on or near the retina.

Etiological factors:

1. **Corneal astigmatism:** When the cornea has irregular curvature on the anterior surface.
2. **Lenticular astigmatism:** astigmatism due to lens irregular surface.
3. **Retinal astigmatism**

Types of astigmatism:

1. **Regular astigmatism:** This type of refractive error demonstrates two principal meridians though the angle between them tends to vary. Different types of regular astigmatism are:
 - a. **With – the – rule astigmatism:** in this type of astigmatism these two aforesaid meridians are perpendicular to each other with vertical component more curved than the horizontal one.
 - b. **Against the rule astigmatism:** this type of astigmatism shows both principal meridians perpendicular to each other but the horizontal meridian is more curved than the vertical one.
 - c. **Oblique astigmatism:** in this type of astigmatism the two principal meridians are perpendicular to each other but not placed in horizontal and vertical locations.
 - d. **Bioblique astigmatism:** in this type of astigmatism the two principal meridians are not perpendicular to each other.
2. **Irregular astigmatism:** this type of astigmatism reflects multiple, difficult to document meridians and the meridians lacks any geometric representations.

Clinical presentation:

1. **Asthenopia:** heaviness/tiredness of the eyes which may leads to vision blurring and frontal headache/heaviness
2. **Reduced vision**
3. **Distortion of the vision** which may lead to head tilting to compensate the anamoly

Diagnostic tools:

1. **Keratometry:** for the analysis of corneal curvature topographic details.
2. **Retinoscopy:** its helps in discovering power of different meridians
3. **Jackson's cross cylinder**
4. **Astigmatic fan test**
5. **Computerised corneal topographic testing**

Optical correction/refraction:

- Spectacles and contact lens of appropriate cylindrical lens is prescribed at suitable axis.
- Phototherapeutic keratectomy(PTK)
- Laser treatment

Anomaly of Accommodation (presbyopia):

- **Definition:** a visual condition which becomes apparent especially in middle age and in which loss of elasticity of the lens of the eye causes defective accommodation and inability to focus sharply for near vision.

Features:

- a. **Progressive:** age-related loss of accommodation
- b. **Early 40s:** Functional vision affected
- c. Complete loss of accommodation by 5th to 6th decade
- d. Most prevalent ocular anomaly
- e. Almost 100% of population is affected

Etiological factors:

1. Lenticular (Lens) Changes
 - a) Lenticular sclerosis
 - b) Changes in capsular elasticity
 - c) Change in zonular insertion angle
2. Extralenticular Changes
 - a) Neuromuscular changes
 - b) Ciliary muscle changes

Stages/types of presbyopia:

1. Incipient presbyopia
2. Functional presbyopia
3. Absolute presbyopia
4. Premature presbyopia
5. Nocturnal presbyopia

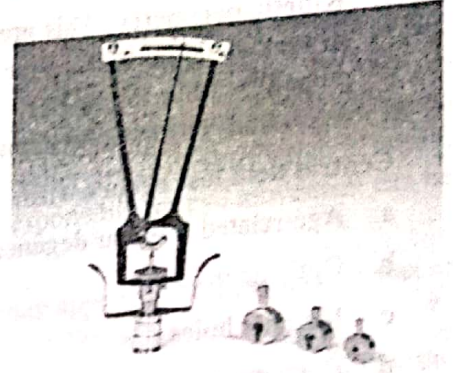
Management:

- a. Prescription of convex lenses (+ lenses) to compensate loss of accommodation power.

- b. Presbyopia can be corrected with reading, bifocal or multifocal eyeglasses, or with bifocal or multifocal contact lenses
- c. Accommodative intraocular lenses
- d. Surgical treatments that reshape the cornea, such as PresbyL aSIK
- e. Corneal keratoplasty procedure (Conductive keratoplasty)

Testing intraocular pressure (IOP):

- The tissue pressure of the intraocular contents is called the intraocular pressure (IOP). The term ocular hypertension usually refers to any situation in which the pressure inside the eye, called intraocular pressure (IOP), is higher than normal. Eye pressure is measured in millimeters of mercury (mmHg). Normal eye pressure ranges from 10 to 21 mmHg. Ocular hypertension is an eye pressure of greater than 21 mmHg.
- **IOP measurement:**
 - a. The gold standard for measurement of IOP is the Goldmann Tonometer. This is an applanation Tonometer, measuring the force necessary to flatten the area of the surface of the cornea.
 - b. Topical anaesthesia to the cornea is required for testing.
 - c. A portable version is available (Perkins) but more commonly seen is the 'air-puff' Tonometer. This device forces a burst of air onto the cornea until it is flat and reflects an emitted light beam. No topical anaesthesia is required.
 - d. Indentation tonometry: an alternative method is indentation tonometry, relying on the measurement of the indentation of the cornea by a known weight. However, this is subject to error by variations in the rigidity and thickness of the sclera.
- **Significance of IOP measurement:** Ocular hypertension is the most important risk factor for glaucoma. Differences in pressure between the two eyes are often clinically significant, and potentially associated with certain types of glaucoma, as well as iritis or retinal detachment.



Testing visual field:

- The field of vision is that portion of space in which objects are visible at the same moment during steady fixation of gaze in one direction. The monocular visual field consists of central vision, which includes the inner 30 degrees of vision and central fixation, and the peripheral visual field, which extends 100 degrees laterally, 60 degrees medially, 60 degrees upward, and 75 degrees downward.
- Visual field defect: a portion of the visual field is missing. This may be central (e.g. An optic disc or nerve problem) or peripheral (along the visual pathways from the optic chiasm back).
- **Scotoma:** this is a type of visual field defect. It is a defect surrounded by normal visual field.
 1. **Relative scotoma** - an area where objects of low luminance cannot be seen but larger or brighter ones can.
 2. **Absolute scotoma** - nothing can be seen at all within that area.
- **Method/instrument:**
 1. **Confrontation visual field testing:** This is a simple (but approximate) method of assessing visual field loss. It is a qualitative measurement but is a good starting point and can easily be carried out in the surgery.

Traditionally a hatpin has been used to define the visual field. A red or a white head is used and it may be moved across the visual field to ascertain where it disappears and hence to define a scotoma.

2. **Static perimetry:** This is the most commonly used assessment. An 'on/off' light signal is presented throughout the patient's potential visual field and the patient clicks every time they see the signal. These automated machines can assess various amounts of the visual field. Few different types of static perimetry tests can be used of which Humphries is the most common.
 3. **Kinetic perimetry:** This presents a moving stimulus from a non-seeing area to a seeing area. It is repeated at various points around the clock and a mark is made as soon as the point is seen. These points are then joined by a line (an isoptre). The process is repeated with a point of lesser luminescence and another isoptre is created. The most commonly used kinetic test is Goldmann's perimetry.
- **Central field loss occurs with:**
 - a. Age-related macular degeneration
 - b. Optic neuropathy
 - c. Macular holes
 - d. Cone dystrophies
 - **Peripheral field loss occurs with:**
 - a. Glaucoma (angle-closure glaucoma and open angle glaucoma)
 - b. Retinal detachment
 - c. Retinitis pigmentosa
 - d. Chorioretinitis

External examination of eye:

- To begin the physical examination of the eye, one should start with the external structures. The eyelids and surrounding areas should be examined for swelling, erythema, warmth, skin growths, and tenderness. Trauma or infection (periorbital cellulites or zoster) may become apparent on evaluation of the peri-orbital region.
- **Proptosis** (forward bulging of the eye) can easily be identified with gross inspection of the orbits. Unilateral proptosis may be caused by orbital cellulitis, orbital hemorrhage, cavernous sinus thrombosis, or tumors. Bilateral exophthalmos is most commonly caused by hyperthyroidism. Proptosis can be quantified by the ophthalmologist using an exophthalmometer.
- **Enophthalmos** may be caused by an orbital blow-out fracture. The bony structures should be palpated to ascertain tenderness.
- Lid evaluation may find ptosis, which may be congenital or acquired. Newly acquired ptosis may represent Horner's syndrome, third nerve palsy, botulism, or myasthenia gravis.
- Inability to close the lids may result from weakness of the orbicularis oculi muscle, as in seventh cranial nerve palsy.
- It is important to flip the upper lid you are searching for a foreign body.
- Careful evaluation of the lids may reveal infections of the lid (lid cellulitis) or dacryocystitis, which is an infection of the tear collection system (puncta, canaliculi, nasolacrimal duct). Other lid findings include hordeolum and chalazion. A hordeolum is an acute inflammation of a meibomian gland, and a chalazion is a chronic obstruction and inflammation of a meibomian gland.

Examination of extraocular movements:

- When testing extraocular movement, special note should be made of the range, symmetry, smoothness, and speed of the eye movements.
- Nystagmus can also be observed. To test these movements, the patient is asked to fixate on a target with both eyes. The examiner then moves the target in four directions.
- Disorders of ocular motility may be caused by cranial nerve dysfunction, extraocular muscle entrapment, or increased pressure within the orbit (orbital cellulitis or hemorrhage).

Strabismus:

It is a visual disorder where the eyes are misaligned and point in different directions. Sometimes, only one eye is affected turning inward (esotropia), outward (exotropia) or downward while the other eye is directed straight ahead. Strabismus can also be described by its cause. The 3 cranial nerves (III, IV, VI) responsible for eye movement can be weak or paralysed.

- This misalignment may be constant, being present throughout the day, or it may appear sometimes and the rest of the time the eyes may be straight (Intermittent).
- Binocular single vision: slightly dissimilar images from both retinas are fused centrally to be interpreted by the brain as a single image.
- Strabismus prevents proper binocular vision and prevents both eyes from gazing the same point. Either peripheral vision or side vision may be affected. A patient's perception of depth is distorted. Perception of depth is the ability to recognize the order of objects in three dimensions. Patients will also experience a limited field of view.

Important words used in context of strabismus:

- a. Strabismus = heterotropias
- b. Esotropia = eyeball turn inward
- c. Exotropia = turn outward
- d. Hypertropia = turn upward
- e. Hypotropia = turn downward
- f. Amblyopia = Lazy eye (vision deficiency in an eye when the brain turns off the visual processing of one eye.
- g. Anisometropia = unequal refractive errors between the two eyes
- h. Diplopia = Double vision
- i. Stereopsis: the construction of a 3D percept to the retinal images which have been taken from different angles.
- j. Versions: Binocular eye movements are called Versions
- k. Ductions: Monocular eye movements with the other eye covered are called Ductions
- Yoke muscles are pair of muscles (one muscle in each eye) moving the eye into the same direction of gaze
 1. Rt. lateral rectus & Lt. medial rectus = helps to see to the right
 2. Lt. lateral rectus & Rt. medial rectus = to the left
 3. Rt. superior rectus & Lt. inferior oblique = to the right & up
 4. Rt. inferior rectus & Lt. Superior oblique = to right & down
 5. Lt. superior rectus & Rt. inferior oblique = to left & up
 6. Lt. inferior rectus & Rt. superior oblique = to left & down

- **Types of strabismus:**
 1. Esotropia—inward turning of the eye
 2. Exotropia—outward turning of the eye
 3. Hypertropia—upward turning of the eye
 4. Hypotropia—downward turning of the eye
- **Other classification:**
 1. Constant or intermittent—the frequency it occurs
 2. Bilateral—both eyes converge or diverge at the same time
 3. Unilateral—if it always involves the same eye
 4. Alternating—when the turning is sometimes the right and other times the left eye
- Of the dozens of different types of strabismus, three types are seen much more commonly in the paediatric population. They are congenital esotropia, accommodative esotropia and intermittent exotropia
- **Diagnosis:**
 1. Cover–Uncover test: a test to detect strabismus; the patient's attention is directed to a small fixation object, one eye is covered and after a few seconds, uncovered; if the uncovered eye moves to see the picture, strabismus is present
 2. Alternate cover test
 3. Hirschberg corneal light reflex
- **Management principles:**
 1. **Eye Patch:** The stronger eye is patched to force the brain to interpret images from the strabismic eye.
 2. **Eyeglass or Contacts lens:** Eyeglasses or Contacts are used to improve the positioning of the eye by modifying the patient's reaction to focus. Eyeglasses and Contacts can also redirect the line of sight, which can help straighten the eye.
 3. **Prisms:** Prisms are used to modify the way light and images hit the eye. The lenses provide comfort and can help prevent double vision from developing.
 4. **Surgery:** Surgery may be necessary in an attempt to align the eyes by modifying one or more muscles in the eye. During surgery, the muscle positions will be changed or the length of the muscles will be changed. Surgery may follow a period of eye patching and then eyeglasses may be used after surgery to help treat strabismus. Two types of surgery is performed:
 - a. **Recession:** incision in the conjunctiva to expose the muscle, muscle is then reinserted on the globe.
 - b. **Resection:** cutting and shortening of the muscle and attaching it to its original position

Amblyopia:

- **Definition:** Lazy eye (amblyopia) is decreased vision that results from abnormal visual development in infancy and early childhood. Although amblyopia usually affects only one eye, it can affect both eyes. Lazy eye is the leading cause of decreased vision among children. Left untreated, vision loss may range from mild to severe.
- In amblyopia, visual stimulation either fails to transmit or is poorly transmitted through the optic nerve to the brain for a continuous period of time. Detecting the condition in early childhood increases the chance of successful treatment, especially if detected before the age of five. The earlier it is detected, and the underlying cause corrected with glasses or surgery, the more successful the treatment in equalizing vision between the two eyes.

- **Types of amblyopia:**

1. **Anisometropia/Refractive amblyopia:** Inhibition of the fovea occurs to eliminate the abnormal binocular interaction caused by one defocused image and one focused image. Small amounts of hyperopic anisometropia, such as 1-2 diopters, can induce amblyopia. In myopia, mild myopic anisometropia up to -3.00 diopters usually does not cause amblyopia.
2. **Strabismus amblyopia:** The patient favours fixation strongly with one eye and does not alternate fixation. This leads to inhibition of visual input to the retinocortical pathways.
3. **Visual deprivation amblyopia:** amblyopia results from disuse or understimulation of the retina. This condition may be unilateral or bilateral. Examples include cataract, corneal opacities, ptosis, and surgical lid closure.
4. **Organic:** Structural abnormalities of the retina or the optic nerve may be present.

- **Physical examination:**

1. **Visual acuity:** Diagnosis of amblyopia usually requires a 2-line difference of visual acuity between the eyes
2. **Crowding phenomenon:** a common characteristic of amblyopic eyes is difficulty in distinguishing optotypes that are close together. Visual acuity often is better when the patient is presented with single letters rather than a line of letters.
3. **Contrast sensitivity:** Strabismic and anisometropic amblyopic eyes have marked losses of threshold contrast sensitivity.
4. **Eccentric fixation:** Some patients with amblyopia may consistently fixate with a nonfoveal area of the retina under monocular use of the amblyopic eye.

- **Management:**

1. Patching may be full-time or part-time: full-time patching produced a similar effect to that of 6 hours of patching per day
2. Opaque contact lenses, occluders mounted on spectacles, and adhesive tape on glasses have been used.

Examination of conjunctiva:

- It is important to evaluate the conjunctiva lining the lids (palpebral conjunctiva) and the conjunctiva on the surface of the eye (bulbar conjunctiva). Conjunctival injection (prominence of vessels) may be diffuse or perilimbal (radiating outward from the limbus, which is where the cornea meets the sclera).
- Diffuse conjunctival injection usually results from inflammation or infection within the conjunctiva itself (conjunctivitis), whereas perilimbal injection may be the result of inflammation or infection within the uvea or anterior chamber. **Chemosis** refers to edema of the conjunctiva.
- Examination of the conjunctiva may also reveal a subconjunctival hemorrhage, which may be spontaneous or traumatic. Although these usually are benign but may be secondary to ruptured globe or coagulopathy.

Examination of sclera and episclera:

- Inflammation of the episclera and sclera may be difficult to distinguish from conjunctivitis. Episcleritis is usually painless and causes injection of a sector of episcleral vessels. These vessels will blanch with application of phenylephrine. Vision usually is preserved. It is self-limited and may be associated with collagen vascular diseases.
- Scleritis causes injection of scleral vessels with a characteristic violaceous color. It is painful and often causes decreased vision. The injection will not clear with topical phenylephrine. It is associated with collagen vascular

diseases and certain infections (zoster, tuberculosis, syphilis). Treatment depends on severity but often includes systemic steroids.

Examination of uveal tissue:

- Inflammation of the anterior uvea (anterior uveitis, iritis, iridocyclitis) can be detected by the associated photophobia and unilateral constricted pupil that results from ciliary spasm as well as cells and flare in the anterior chamber. Causes include trauma, viral, Reiter's Syndrome, sarcoidosis, juvenile rheumatoid arthritis, and retinoblastoma, and it often is idiopathic.
- The iris should also be examined for traumatic tears at the papillary margin and for iridodialysis (separation of the iris from the ciliary body).
- Inflammation of the posterior uvea can be seen as exudates around retinal vessels and hazy vitreous humor. It can be caused by cytomegalovirus, toxoplasmosis, sarcoidosis, syphilis, herpes, and other causes.

Examination of cornea:

- Corneal evaluation is accomplished with the aid of proparacaine, fluorescein, and the slit lamp. Defects in the corneal surface will appear bright yellow-green under the cobalt blue light on the slit lamp when stained with fluorescein.
- It is an essential part of the emergency eye examination to carefully evaluate the cornea with the slit lamp for foreign bodies, abrasions, and ulcerations. Many causes of infection and inflammation of the cornea (keratitis) have specific patterns of fluorescein uptake on slit lamp examination (herpes simplex, herpes zoster, adenovirus, ultraviolet keratitis).
- Corneal edema, seen in acute angle closure glaucoma, will appear to the examiner as a "steamy" cornea, and the patient will see "halos" around lights.

Examination of pupil:

- On gross examination, the pupils are symmetric and circular. As many as 20% of normal individuals may have anisocoria (unequal pupils) of less than 1 mm.
- anisocoria also may be caused by uveitis, trauma, uncal herniation, oculomotor nerve palsy, or Horner's Syndrome and iatrogenically by dilating or constricting drops or nebulized ipratropium.
- The examiner should test the pupils' response to direct light. As the pupil reacts to direct light, a consensual response (constriction of the opposite pupil) will also occur. After the examiner notes the degree and speed of response of both the direct and consensual response in each eye, one should swing the light between the two eyes (swinging flashlight test).
- Each pupil should constrict with both direct and consensual light. If the pupil dilates as the light is swung to it from the opposite pupil, this means that the pupil constricts more vigorously to consensual light than direct light, the hallmark of an afferent papillary defect. This is referred to as a "Marcus Gunn pupil".

Examination of anterior chamber:

- **Hyphema** (blood in the anterior chamber) and **hypopyon** (layer of white blood cells/pus in the anterior chamber) often can be seen without magnification, but a slit lamp evaluation is essential to adequately evaluate the anterior chamber.

- With a slit lamp, inflammation of the anterior chamber will be seen as cells (WBCs floating in the aqueous) and flare (increased protein causing the aqueous to appear cloudy). Cells and flare in the anterior chamber can be seen in uveitis, scleritis, and trauma.
- Gonioscopy describes the use of a gonioleus (also known as a gonioscope) in conjunction with a slit lamp or operating microscope to gain a view of the iridocorneal angle, or the anatomical angle formed between the eye's cornea and iris. The importance of this process is in diagnosing and monitoring various eye conditions associated with glaucoma.

Ophthalmoscopy/ fundoscopy:

- The use of a hand-held ophthalmoscope enables the examiner to visualize the fundus. In a darkened room, the patient fixes his vision across the room, and the examiner then brings the ophthalmoscope as close as possible to examine each eye. The dial on the ophthalmoscope can then be adjusted to focus the image. This allows for examination of the structures in the retina. The examiner notes the optic disk, the vasculature, and the macula.
- **Types of Ophthalmoscopy:**
 1. **Direct ophthalmoscopy:** one that produces an upright, or unreversed, image of approximately 15 times magnification.
 2. **Indirect ophthalmoscopy:** one that produces an inverted, or reversed, direct image of 2 to 5 times magnification.
- Dilation of the pupil can assist in the visualization of the retina. Examination of the periphery of the retina requires the use of an indirect ophthalmoscope.

Clinical examination of lacrimal apparatus:

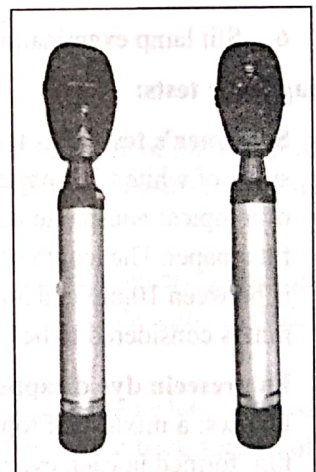
Tears which are produced by the main and accessory lacrimal glands are mostly drained by the lacrimal drainage system. Any disorder affecting the lacrimal system causes the complaint of tearing (epiphora). Excessive tearing could be caused by hypersecretion from the tear glands or insufficient drainage of tears through the lacrimal drainage system (epiphora).

Introduction of tear film:

- The tear film (10 μm thick) covers the external ocular surface and comprises three layers:
 1. Thin mucin layer in contact with the ocular surface and produced mainly by the conjunctival goblet cells
 2. An aqueous layer produced by the lacrimal gland
 3. A surface oil layer produced by the tarsal meibomian glands and delivered to the lid margins.

The functions of the tear film are as follows:

1. It provides a smooth air/tear interface for distortion free refraction of light at the cornea
2. Provides oxygen anteriorly to the avascular cornea
3. It removes debris and foreign particles from the ocular surface through the flow of tears
4. It has antibacterial properties through the action of lysozyme, lactoferrin and the immunoglobulins, particularly secretory IgA.



• **The examination includes:**

1. Inspection of the eyelid position, contour and function in relation to the operation of the lacrimal pump. Malpositions of eyelid such as ectropion, where in the punctum is not apposed to the globe, will always be associated with epiphora.
2. Facial nerve palsy may lead to paralytic ectropion / weakness of orbicularis muscle. Weakness of orbicularis oculi may affect the lacrimal pump mechanism. Contractions and relaxations of orbicularis oculi is necessary for tears to be pumped into the lacrimal sac.
3. Punctal abnormalities: Punctal ectropion may be associated with epiphora. Each punctum should be assessed for patency. Normal punctum is usually 0.3 mm in diameter. Congenital/acquired stenosis of the punctum may interfere with tear drainage mechanism. Swelling/erythema around the punctum may signify canaliculitis. In these cases pressure over the canaliculus may cause tear reflux, while pressure over lacrimal sac area does not show any reflux. The canalicular area should be palpated carefully to seek evidence of canaliculitis.
4.
 - a. Palpation over the medial canthal area may reveal a mass in the area of lacrimal sac, in patients with significant lower tear drainage channel obstruction. Lacrimal sac tumors must be diligently excluded by palpating this area. In patients with significant lower lacrimal drainage channel obstruction, palpation over lacrimal sac area will cause pain with reflux of tears / secretions / pus. If the reflux is purulent then significant dacryocystitis should be suspected.
 - b. In patients with complete obstruction of lacrimal drainage system, infection commonly develops in the lacrimal system causing swelling, redness, and tenderness in the medial canthal region. Lacrimal sac infections (dacryocystitis) are associated with pain around the eye. In pediatric patients this may progress to orbital / periorbital cellulitis.
5. Intranasal examination: This is a must. All suspected patients should undergo diagnostic nasal endoscopic examination to rule out sinonasal causes of lacrimal outflow obstruction.
6. Slit lamp examination: Will reveal elevation of precorneal tear film.

Diagnostic tests:

- a. **Schirmer's test:** This test is basically prepared to quantitative tear production. This test is performed by placing strips of white filter paper at the junction of the middle and lateral thirds of the lower eyelids after administration of a topical anesthetic agent. The tear production is measured with the eyes closed. Produced tears will wet the filter paper. The length of the filter paper which becomes wet is assessed at the end of 5 minutes. Normal test result is between 10mm and 30 mm of wet filter paper. Normally it should not exceed 30 mm. A value of more than 30 mm is considered to be epiphora. A value of less than 10 mm is considered to be **dry eye** (hyposecretion).
- b. **Fluorescein dye disappearance test:** This test can be easily performed as an office procedure. The steps are as follows: a mixture of topical anesthetic and fluorescein dye is placed in the inferior fornix of each eye. The tear film formed in each eye is observed and compared over a period of 5 - 10 minutes.
- c. This dye should drain rapidly through a patent lacrimal drainage system. Persistence of dye in the tear film even after 10 minutes indicates abnormal lacrimal outflow. This could be due to functional / anatomic obstruction in the lacrimal drainage apparatus.
- d. **Punctal dilatation and canalicular probing:** This simple test is used to evaluate patency of the proximal ductal system. Difficulty with dilatation may indicate clinically significant punctal stenosis. Similarly difficulty with probing through the canaliculus may indicate canalicular stenosis / stricture. This is a contraindication for endoscopic DCR. Drainage may improve if probing opens up the stenosed canaliculi. Easy probing up to the superior portion of lacrimal sac is a good indicator of upper lacrimal drainage pathway patency.

- e. **Lacrimal irrigation:** This test is used to diagnose the location and extent (complete / partial) of an obstruction. A 23 - 27 gauge cannula is attached to a syringe containing sterile saline solution. This is introduced into the proximal canaliculus (usually the lower one) following punctal dilatation. Irrigation should be performed in both eyes even in patients with unilateral epiphora, since the normal eye can be used as the basis of comparison. In the presence of patent / partially patent lacrimal system the saline finds its way into the nasal cavity. Reflux of the injected saline through the same punctum indicates canalicular obstruction, while reflux from the opposite punctum indicates obstruction distal to the common canaliculus. Distention of lacrimal sac or reflux of purulent secretion indicates nasolacrimal duct obstruction. Reflux of bloody fluid indicates lacrimal system inflammation, a lacrimal sac tumor, or trauma to the tissues while introducing the cannula.
- f. **Jones dye tests:** These groups of tests are used to distinguish between functional and anatomic outflow problems. The primary test is performed by placing topical anesthetic and fluorescein dye into the conjunctival sac. Topical 4% Xylocaine and oxymetazoline nasal sprays may be used to anesthetize and vasoconstrict the inferior meatus of the nose. Cotton tipped applicator is placed beneath the inferior turbinate near the opening of the nasolacrimal duct. Recovery of fluorescein dye in the nose indicates a functionally and anatomically patent system. Non recovery of the dye (negative result) suggests a functional or anatomic blockage.
- g. In the event of negative dye test, secondary dye test should be performed. This test is performed after removal of residual fluorescein from the conjunctival sac. Clear saline solution is placed into the inferior canaliculus using a syringe / cannula. The irrigant is retrieved from the nasal cavity by tilting the patient's head forward over a basin. If fluorescein dye is present in the irrigant (positive result) then it is assumed that the upper lacrimal system is functional while the lower system is partially open and is not functional.
Recovery of a clear irrigant (negative result) indicates a functional problem with the upper system.
- h. **Dacryocystogram:** This test helps to evaluate the anatomy of the lacrimal system. In this test contrast medium is injected into the lacrimal system through the lower canaliculus, and performing a serial radiography. The anatomy of the complete outflow system becomes visible. This test is useful in identifying congenital anomalies involving the lacrimal outflow tract.

Physiology of vision:

Light waves from an object enter the eye first through the cornea, which is the clear dome at the front of the eye. It is like a window that allows light to enter the eye. The light then progresses through the pupil, the circular opening in the center of the colored iris.

- Fluctuations in the intensity of incoming light change the size of the eye's pupil. As the light entering the eye becomes brighter, the pupil will constrict (get smaller), due to the pupillary light response. As the entering light becomes dimmer, the pupil will dilate (get larger).
- Initially, the light waves are bent or converged first by the cornea, and then further by the crystalline lens (located immediately behind the iris and the pupil), to a nodal point (N) located immediately behind the back surface of the lens. At that point, the image becomes reversed (turned backwards) and inverted (turned upside-down).
- The light continues through the vitreous humor, the clear gel that makes up about 80% of the eye's volume, and then, ideally, back to a clear focus on the retina, behind the vitreous. The small central area of the retina is the macula, which provides the best vision of any location in the retina. If the eye is considered to be a type of camera (although, an extremely complex one), the retina is equivalent to the film inside of the camera, registering the tiny photons of light interacting with it.
- Within the layers of the retina, light impulses are changed into electrical signals. Then they are sent through the optic nerve, along the visual pathway, to the occipital cortex at the posterior (back) of the brain. Here, the electrical signals are interpreted or "seen" by the brain as a visual image.

Visual pathway: The axons of the ganglion cells exit the eye at the level of the lamina cribrosa, collectively forming the optic nerve. Each optic nerve consists of approximately 1 million retinal ganglion cell axons. The area where the axons exit the eye is called the optic disc. Because no receptors exist in this region, nothing can be seen in the corresponding part of the visual field.

Central projection:

- **Formation of optic chiasm:** The optic nerves of the 2 eyes continue posteriorly and meet at the optic chiasm, located just anterior to the stalk of the pituitary gland.
- At the optic chiasm, the optic nerves decussate. The axons from the nasal retina cross over to the opposite (i.e. contralateral) side of the brain, and the axons from the temporal retina project ipsilaterally.
- **Optic tract:** after the axons of the ganglion cells pass the optic chiasm, they are collectively referred to as the optic tract. Posterior to the optic chiasm, the information carried from the left visual field is carried in the right optic tract, whereas the information from the right visual field is carried in the left optic tract. Each optic tract terminates at the lateral geniculate nucleus (LGN), which is the visual part of the dorsal thalamus.
- **Lateral geniculate nuclei (LGN):** The vast majority of the axons of the right and left optic tracts terminate in the right and left LGNs. The LGN serves as the primary relay nucleus for visual processing by the cerebral cortex. The right LGN receives information from the left visual field via the right optic tract, and the left LGN receives information from the right visual field via the left optic tract.
- **Optic radiation and occipital cortex:** Most of the axons from LGN neurons from the optic radiations, which terminate in the visual areas in the occipital cortex. Fibers in the optic radiation that carry information about the superior visual field sweep around the lateral horn of the ventricle in the temporal lobe before reaching the occipital cortex. The topographic order of visual information and the final processing of the neural signals from the retina are maintained in the visual cortex. The fovea is represented in the posterior part of the visual cortex, and the more peripheral regions of the retina are represented in progressively more anterior regions.

Basic sense of the visual pathway:

The axons of the retinal ganglion cells form the optic nerve. The two optic nerves meet at the optic chiasm, where the nerve fibers originating in the nasal retina of each eye decussate to join the temporal fibers of the fellow eye. From the chiasm, the same axons continue on as the optic tract. These axons travel to and synapse in the lateral geniculate nucleus, the cells of which send their axons through the optic radiations to the visual cortex.

संधिगत रोग प्रकरण

“पूयालसः सोपनाहः स्रावाः पर्वणिकाऽलजी।

क्रिमिग्रन्थिश्च विज्ञेया रोगाः सन्धिगता नव।।” सु.उ. 2/3

पूयालस

सुश्रुतानुसार/भावप्रकाश/यो.र.

“पक्वः शोफः सन्धिजः संस्रवेद्यः सान्द्रं पूयं पूति पूयालसः सः।” सु.उ. 2 / 4

नेत्र की कनीनक सन्धि में पहले शोफ होकर वह पाक के पश्चात् सान्द्र (घन) तथा दुर्गन्धित पूय के रूप में स्राव होता है → पूयालस।

डल्हण टीका:

इदानीं तेषां नवानामपि प्रत्येकं लक्षणमाह - पक्व इत्यादि। सन्धिजः कनीनकसन्धिजः। पूति दुर्गन्धम्। अयं सन्निपातजः साध्यश्च।।

वाग्मट्टानुसार-

“पूयालसो व्रणः सूक्ष्मः शोफसरम्मपूर्वकः।

कनीनसन्धावाध्यायी पूयास्रावी सवेदनः। अ.ह.उ. 10/7

- इस व्याधि में नेत्र की कनीनक सन्धि में शोथ सहित एक छोटा सा व्रण हो जाता है। उसके फूटने पर उससे पीड़ा सहित पूयस्राव होता है।
- जब पूय का स्राव रुक जाता है तो उसी स्थान पर आध्यमान भी हो जाता है।

चिकित्सा प्रकरण -

सुश्रुतानुसार - वेध्य।

“पूयालसे शोणितमोक्षणंचहितं तथैवाप्युपनाहनंच।

कृत्स्नो विधिश्चेक्षणपाकघाती यथाविधानं भिषजा प्रयोज्यः।।”(रक्ताभिष्यन्दप्रतिषधोध्याय) सु.उ. 12/45

- पूयालस में रक्तमोक्षण और उपनाह दोनों के करना हितकारी होता है।
- नेत्रपाक की नाशक सम्पूर्ण विधि शास्त्रानुसार करें।
- कासीसादि रसक्रियांजन-:कासीस + सैन्धव + आद्रक → शहद में अच्छी तरह खरल → अंजन।
- इन्ही द्रव्यों में ताम्र + लौह चूर्ण या भस्म → शहद से मिलाकर खरल → अंजन प्रयोग।

वाग्मट्टानुसार - पूयालस यदि चिकित्सा करने पर शांत न हो तो सूक्ष्मशलाका से दहनकर्म

- “उपनाह कृमिग्रन्थि पूयालस पर्वणीः।
शस्त्रेण साधयेत्पंच सालजीनास्रवांस्त्यजेत।।” उ. 10/4

Dacryocystitis

Introduction:

- Dacryocystitis is an inflammation of the lacrimal sac, frequently caused by nasolacrimal duct obstruction or infection. It causes pain, redness, and swelling over the inner aspect of the lower eyelid and epiphora. It is represented in two type acute dacryocystitis and chronic dacryocystitis. Typically infants and adults over 40 years of age are affected. Most common bacteria engaged are streptococcus and staphylococcus group.

- **Epiphora:** this is the commonest presentation of lacrimal pathologies. Tearing of eye may have two etiological factors, first one are when there is excessive tear production like seen in conjunctival and corneal infections/irritations. The second group of etiological factors is represented by obstructive pathology of the drainage system at various levels; this particular group has got the nomenclature 'Epiphora' for tearing. This group includes punctal misdirection and obstructions, canalicular impediments, lacrimal sac obstruction and more frequently a NLD blockage.

Types of Dacryocystitis:

1. Chronic dacryocystitis:

- Predisposing factors:
 - a. Abnormally narrow nasolacrimal duct (NLD) anatomically which may impede the lacrimal drainage system.
 - b. Associated inflammation viz. conjunctivitis may block the sac or NLD with mucus plugs and desquamated epithelial cells.
 - c. Rhinological causes like deviated nasal septum/spurs, extensive polypoidal mucosa, growth/tumor of the nasal cavity, anterior nasal packing done to control epistaxis and massive inferior turbinate hypertrophy may block NLD opening in the inferior meatus thus precipitating dacryocystitis.
 - d. Abnormal mucosal folds and strictures in the sac or NLD and lacrimal sac foreign bodies.
- Clinical features:
 - a. Epiphora, cystic swelling over the lacrimal sac (just below the inner canthus) that indicates a mucocele formation.
 - b. Regurgitation of mucopurulent or frank pus from the puncta, when the lacrimal sac external swelling is pressed. Sometimes due to continued chronic infection opening of both the canaliculi in the sac are blocked and a large fluctuant swelling is seen at the inner canthus with a negative regurgitation test. This is called **encysted mucocele**. Mucocele is the commonest swelling of the lacrimal sac.

Complications:

- Chronic indolent conjunctivitis
- Hypopyon ulcer
- Post surgical complication (intraocular surgeries) including endophthalmitis.
- Atonic lacrimal sac leading to lacrimal pump failure (excessive fibrosis of the sac wall) and sac can only be evacuated with pressing it manually.

Management:

- **Non surgical/conservative:** repeated syringing and antibiotic eye drops are tried which may leads to a successful outcome in limited number of patients but must be tried in relatively recent cases.
- **Surgical management:**
 - a. **DCR (Dacryocystorhinostomy):** this can be done via external and endoscopic endonasal approach and is operation of choice in managing chronic dacryocystitis. The later technique is now more preferred method and recommended/performed because it does not cause an external scar and being less invasive with equally good results (> 90% in expert hands). DCR aims at bypassing the obstructed NLD and making a surgical connection directly between the lacrimal sac and the nasal cavity. A vertical incision is made just anterior to the anterior margin of the middle turbinate and the overlying bone is removing with a drill or a bone punch

in order to expose the lacrimal sac. Sac wall is then incised and silicon stents is placed which protect the surgically created window for closure in the nasal cavity during the healing phase.

External or conventional DCR is done by making a curved incision along the anterior lacrimal crest. Medial palpebral ligament is sectioned and lacrimal sac is exposed which then is reflected laterally to have a good view of the lacrimal fossa. Lacrimal bone is pierced to enter the nasal cavity. Medial wall of the lacrimal sac is incised vertically to create anterior and posterior flaps which are secured and a surgical window is completed between the lacrimal sac and the nasal cavity.

- b. **DCT (Dacryocystectomy):** it is rarely indicated and this surgical operation includes sacrifice of the irreparable lacrimal sac. Common indications of DCT are lacrimal sac malignancy, non functional and extremely fibrosed lacrimal sac which will make a DCR worthless, tuberculosis of the lacrimal sac and limited skilled surgeon to perform DCR.
- c. **Conjunctivodacryocystorhinostomy and canaliculodacryocystorhinostomy**

2. Congenital dacryocystitis:

- This is defective canalization of the lacrimal drainage system in newborns; most notable obstruction is the lower end of NLD by mucosal fold abnormalities and epithelial debris obstruction. Common pathogens recovered are Haemophilus influenzae, Staphylococcus aureus and Streptococcus species.
- **Clinical features:** Mucopurulent discharge regurgitation, matting of the eyelashes, visible swelling of the sac area and epiphora.
- **Management:**
 - a. **Milking and massage of the sac:** this technique is found to be most effective in managing congenital dacryocystitis especially of very young age (upto 4 wks). This technique includes expression or milking of the sac with firm massaging it from upside down with 10-15 strokes, 3-4 times a day. This is usually followed by topical antibiotic eye drop instillation. While performing this manoeuvre index finger is used to block common canaliculi in order to prevent the reflux/regurgitation.
 - b. **Lacrimal syringing:** in failed cases of the congenital dacryocystitis frequent syringing is done with normal saline or antibiotic solution through upper and lower puncta.
 - c. **Lacrimal probing:** if the congenital dacryocystitis fail to respond even after 10-12 months than lacrimal probing is done with Bowman's probe from the upper punctum. The rationale of waiting this much of period is that spontaneous opening of the blockage occurs in more than 95% of the cases with lacrimal sac massage and syringing. Upper punctum is dilated with Nettleship punctum dilator and a lacrimal probe is inserted through the lacrimal pathway upto the nasal cavity. Utmost care must be entertained not to injure the canaliculi and other structures. This is followed by frequent syringing to maintain the patency of the established drainage pathway. This technique requires general anesthesia to be performed, repeated probing may cause extensive traumatic fibrosis of the pathway and false passage formation thus not recommended.
 - d. **DCR (Dacryocystorhinostomy):** rarely needed.

3. Acute dacryocystitis:

It is painful suppurative inflammation of the lacrimal sac. Etiological factors include acute exacerbation of chronic dacryocystitis and ethmoidal cells infection.

- **Clinical features:**
 - a. Painful cellulitis of the lacrimal sac which may involve cheek and lids.
 - b. Epiphora

- c. Lacrimal abscess: when the swelling is organized and the sac is filled with infected purulent material. A cystic swelling is conspicuous at the sac area which is tender. Pointing of the pus may take place which invariably will rupture through skin forming an 'external lacrimal fistula'.
- d. Febrile illness.
- e. Skin overlying lacrimal sac is reddish and indurated.
- **Complications:** corneal ulceration, infective conjunctivitis, orbital cellulitis and facial cellulitis.
 - **Management:**
 - a. Oral broad spectrum antibiotics
 - b. Local application of antibiotic ointment/cream
 - c. Incision and drainage of the lacrimal abscess: most prominent and dependent point must be given a stab incision and the pus is exteriorized followed by a sterile antiseptic dressing.
 - d. Persistent discharging lacrimal fistula warrant a timely done DCR after the acute fulminating condition has subsided.

उपनाह

सुश्रुतानुसार/भा.प्र./यो.र. -

“ग्रन्थिर्नाल्पो दृष्टिसन्धावपाकः कण्डूप्रायो नीरुजस्तूपनाहः।।” सु.उ. 2/4

इस व्याधि में नेत्र संधि में बड़े आकार की व नहीं पकने वाली (अपाकी) एवं कुछ कण्डूयुक्त व वेदनारहित ग्रन्थि उत्पन्न होती है उसको 'उपनाह' कहते हैं।

डल्हण टीका- ग्रन्थिरित्यादि। नाल्पो महानित्यर्थः। अपाक इर्षत्पाकः। उपनाहः श्लेष्मोपनाहः कफजोऽयं साध्यश्च।।”

वाग्मदटानुसार -

“कफेन शोफस्तीक्ष्णाग्रः क्षारबुद्बुदकोपमः।

पृथुमूलबलः स्निग्धः सवर्णो मृदुपिच्छिलः।।

महानपाकः कण्डूमानुपनाहः स नीरुजः”।। अ.ह.उ. 10/3

- कफ दोष के प्रकुपित होने से जो व्रणशोथ आगे से तीक्ष्ण, क्षारपाक के समय उठने वाले बुद्बुद जैसे विस्तृत (फैला हुआ) होता है।
- यह शोथ बलवान, पिच्छिल, त्वचा के वर्ण का, मृदु, महान, अपाकी, कण्डूयुक्त व पीड़ारहित 'उपनाह' कहलाता है।

चिकित्सा प्रकरण -

क) सुश्रुतानुसार - (भेदन + लेखन)

“भित्तवोपनाहं कफजं पिप्पलीमधुसैन्धवैः।

लेखयेन्मण्डलाग्रेण समन्तात् प्रच्छयेदपि।।” सु.उ. 14/9 (भेद्यरोग प्रतिषेध अध्याय)

- इस व्याधि में सम्यक् भेदनकर्म करने के पश्चात् → पिप्पली, मधु व सैन्धव लवण का प्रतिसारण करें।
- महान तथा पीडा रहित उपनाह में मण्डलाग्र शस्त्र द्वारा लेखन कर्म करना।
- रक्तानुबन्धी उपनाह में प्रच्छान् के पश्चात् → प्रतिसारण कर्म करना चाहिए।

ख) वाग्मदटानुसार-

“उपनाहं मिषक् स्वन्नं मिन्नं व्रीहिमुखेन च।

लेखयेन्मण्डलाग्रेण ततश्च प्रतिसारयेत्।।

पिप्पलीक्षौद्रसिन्धुत्थैर्बध्नीयात्पूर्ववत्ततेः।

पटोलपत्रामलक क्वाथेनाश्च्योतयेच्च तम् ।।' अ.सू.उ. 11/1,2

- गरम पानी में भिगोकर पोटली द्वारा नेत्रमण्डल का स्वेदन करके → त्रीष्टिमुख नामक शस्त्र से भेदन करें।
- मण्डलाग्र शस्त्र द्वारा लेखनकर्म करके पिप्पली तथा सैन्धव लवण के घूर्ण को मधु में मिलाकर प्रतिसारण करें।
- तदनन्तर पूर्ववत् लेखन विधि के अनुसार प्रक्षालन, अभ्यंग तथा जी का आटा की पिण्डी रखकर बन्धन कर्म करें → पाँचवे दिन पट्टी खोल दें।
- तत्पश्चात् पटोल पत्र तथा आमलकी क्वाथरस से आश्च्योतन करें।

Mucocele and pyocoele of the lacrimal sac

Mucocele: It follows chronic inflammatory product stagnation causing distention of lacrimal sac in chronic dacryocystitis with both proximal (common canaliculus) and distal blockage (Nasolacrimal duct) of lacrimal apparatus. This fluctuant swelling is seen just below the inner canthus in lacrimal sac area typically with a negative regurgitation test (pressing the swelling does not yield anything from lower punctum).

Patient has got constant epiphora and the sac is filled with entrapped mucoid secretions. This particular condition is called 'mucocele' or 'encysted mucocele'.

Pyocoele: mucoid content of the encysted mucocele may be invaded by pus forming bacteria which convert mucoid secretion to a frank pus. Proximal and distal structures remains blocked with again a negative regurgitation test. Clinical features are epiphora, swelling of the sac area and repeated conjunctivitis.

नेत्रसाव / नेत्रनाड़ी

सुश्रुतानुसार / भाव0प्र0 / यो0र0-

"गत्वासन्धीनश्रुमार्गेण दोषाः कुर्युः स्रावान् रुग्विहीनान् कनीनात् ।

तान् वै स्रावान् नेत्रनाडीमथैके तस्या लिंगकीत्तयिष्ये चतुर्धा ।।" सु.उ. 2/5

- इस व्याधि में मिथ्या आहार-विहार एवं अन्य कारणों से प्रकृषित हुए वातादि दोष → अश्रुमार्ग के द्वारा संधियों में जाकर कनीनक प्रदेश से पीड़ा रहित स्रावों को करते हैं → नेत्र साव नामकरण।
- कुछ आचार्य उन स्रावों को नेत्रनाड़ी कहते हैं।

पूयासाव - पाकः सन्धौ संस्रवेद्यश्च पूयं पूयासावो नैकरूपः प्रदिष्टः ।

श्लेष्मासाव- श्वेतसान्द्रं पिच्छिलं संस्रवेद्यः श्लेष्मासावो नीरुजः सः प्रदिष्टः ।

रक्तासावः -रक्तासावः शोणितोत्थः सरक्तमुष्णं नाल्पं संस्रवेन्नातिसान्द्रम् ।

पित्तासाव- पीताभासं नीलमुष्णं जलामं पित्तासावः संस्रवेत् सन्धिमध्यात् ।।' सु.उ. 2/6-7

चतुर्विधस्त्राव लक्षण-

- 1) सन्धि प्रदेश में पाक होने पर वहां से पूय स्त्रवित होता है → पूयास्त्राव।
- 2) जो स्त्राव श्वेत, सान्द्र, पिच्छिल, तथा पीडारहित होता है → श्लेष्मास्त्राव।
- 3) रक्त की विकृति से उत्पन्न एवं रक्तयुक्त उष्णता सहित एवं अधिक मात्रा में तथा नातिसान्द्र जो स्त्राव होता है → रक्तस्त्राव।
- 4) पीत वर्ण का आभास सहित तथा नील वर्ण, उष्ण और जल के समान द्रव स्त्राव जो कनीनक सन्धि के मध्य से होता है → पित्तास्त्राव।

विमर्श-

सुश्रुतोक्त 'पित्तासाव' के स्थान पर 'हृदयकार' एवं 'संग्रहकार' ने 'जलासाव' को स्वीकार किया है।

वाग्भट्टानुसार -

1) जलास्राव

“वायुः कुद्धः सिराः प्राप्य जलामं जलवाहिनीः।

अश्रु स्रावयते वर्त्मशुक्लसन्धेः कनीनकात्।।

तेन नेत्र सरुग्राग्रशोफं स्यात्सजलास्रावः।” अ.ह.उ. 10/1

विभिन्न प्रकोपक कारणों से वातदोष प्रकुपित होकर → सिराओं में पहुँचकर वर्त्म एवं शुक्लभाग की कनीनिका से जल के समान अश्रु का स्राव कराता है → जलस्राव। इस रोग के कारण नेत्र में पीड़ा, लालिमा तथा शोथ हो जाता है। इसका नाम जलास्राव है।

2) कफास्राव-: कफात् कफास्रवे श्वेत पिच्छिलं बहलं स्रवेत्।

कफास्राव में श्वेत पिच्छिल व बहल स्राव कनीनक संधि से।

3) रक्तास्राव-: रक्ताद् रक्तास्रवे ताम्रं बहूष्णं चाश्रु संस्रवेत्।।

रक्तस्राव में रक्त वर्ण, उष्ण, ताम्र वर्ण का कनीनक संधि से स्राव।

4) पूयास्राव-: पूयास्रवे मलाः स्रासं वर्त्मसन्धेः कनीनकात्। स्रावयन्ति मुहुः पूयं सास्रं त्वङ्मांसपाकतः।।”

पूयास्राव में मलयुक्त क्लेदयुक्त से बारंबार पूयसमान रक्तमिश्रित का स्राव कनीनक संधि से होता है। यह त्वचा व मांस में पाक करती है।

चिकित्सा प्रकरण-

- सुश्रुतानुसार एवं अष्टांगहृदयानुसार असाध्य है।

योगरत्नाकर चिकित्सा-

क) “सावेषु त्रिफलाक्वाथं यथादोषं प्रयोजयेत्।

क्षौद्रेणाऽज्येन पिप्पल्यामिश्रं विध्येच्छिरां तथा।।” यो०र० उत्तरार्धनेत्रचिकित्सा

○ नेत्रस्राव में दोषानुसार त्रिफला क्वाथ में मधु, गोघृत व पिप्पली चूर्ण का क्रम से प्रक्षेप मिलाकर पिलाना चाहिए।

○ शिरा वेधन करना चाहिए।

ख) “पथ्याक्षघात्रीफलमध्यबीजै सिद्धयेकभागैर्विर्दधीत वर्तिम्।

तयांजयेदसमतिप्रवृद्धमक्ष्णोर्हरेत कष्टमपि प्रकोपम्।।”

हरीतकी, विभितक व आमलकी के बीज का सार भाग क्रम से तीन, दो व एक भाग लेकर → जल में पीसकर → वर्तिनिर्माण → अंजन कर्म अत्यंत बड़े हुए स्राव भी नष्ट हो जाते हैं।

ग) कार्पासादयंजनः

“कार्पासीफलजम्बाम्रजलघृष्टं रसांजनम्।।

मधुयुक्तं चिरोत्थं च चक्षुःस्रावमपोहति।।

कार्पास फल + जम्बू + आम्र → जल में घिसना + रसांजन + मधु → वर्ति निर्माण → अंजन प्रयोग → चिरकालिक स्राव नाशक।

स्राव - Possible comparison with modern counter part: this disease identity may be compared with chronic dacryocystitis with patent upper and lower punctum/canaliculi (Please see page no - 59)

पर्वणी

सुश्रुतानुसार/भा.प्र./यो.र.-

“ताम्रातन्वी दाहशूलोपपन्ना रक्ताज्जेया पर्वणी वृत्तशोफा।” सु.उ. 2/8

○ रक्त की विकृति → कृष्ण और शुक्लमण्डल की सन्धि में ताम्रवर्ण का तनु, वृत्ताकार शोफ होता है।

○ दाह व शूल जैसे लक्षण होते हैं → उसे पर्वणी कहते हैं।

वाग्भट्टानुसार-

“वर्त्मसन्ध्याश्रया शुक्लेपिटिका दाहशूलिनी।

ताम्रा मुद्गोपमा भिन्ना रक्तं स्रवणि पर्वणी।।” अ.ह.उ. 10/5

- वर्त्म तथा शुक्ल नेत्र मण्डल की सन्धि में उत्पन्न पिडका।
- दाह तथा शूल युक्त।
- वर्ण ताम्रधातु के सदृश हो।
- आकार में मूंग के बराबर हो।
- भिन्न होने/फूटने पर जिसमें से रक्तास्राव होता हो → उसे 'पर्वणी' कहते हैं।

पर्वणी चिकित्सा प्रकरण-

सुश्रुतानुसार -“सन्धौसंस्वेद्य शस्त्रेण पर्वणीकां विचक्षणः।

उत्तरे च त्रिभागे च बडिशोनावलम्बिताम्।।

छिन्धात् ततोऽर्द्धमग्रे स्यादश्रुनाडी ह्यतोऽन्यथा।

प्रतिसारणमत्रापि सैन्धवक्षौद्रमिष्यते।।

लेखनीयानि चूर्णानि व्याधिशेषस्य भेषजम्।।” सु.उ. 15/23-24 (छेद्यरोगप्रतिषेध)

- इस रोग में प्रथम कृष्ण तथा शुक्ल भाग के सन्धिप्रदेश का स्वेदन करें → बडिश के द्वारा तृतीयांश भाग को पकड़कर खींच कर फिर उसी अग्रभाग के आधे भाग को शस्त्र से काट दें।
- अधिक छेदन से 'अश्रुनाडी' का भय रहता है।
- शेष भाग पर सैन्धवलवण व मधु द्वारा प्रतिसारण कर्म।
- फिर भी व्याधि शेष रह जाए तो विविध लेखनीय चूर्णों द्वारा अंजन या प्रतिसारण कर्म करना चाहिए।

अष्टांगहृदयानुसार -

“पर्वणी बडिशोनात्ता बाह्यसन्धित्रिभागतः।

वृद्धिपत्रेण वर्ध्याऽर्धे स्यादश्रुगतिन्यथा।।

चिकित्साचार्मवत्क्षौद्रसैन्धवप्रतिसारिता।। अ.ह.उ. 11/3

- पर्वणी के बाहरी भाग के तृतीयांश भाग को बडिश यन्त्र द्वारा पकड़कर → वृद्धिपत्र शस्त्र द्वारा आधे भाग से काट दें।
- इससे अधिक छेदन कर देने पर अश्रुनाडी का भय होता है।
- इसकी शेष चिकित्सा अर्मरोग की भांति करनी चाहिए तथा इसमें यथाविधि प्रतिसारण → सेंधानमक के चूर्ण को → मधु में मिलाकर करें।

Benign conjunctival tumors

- Common benign tumors of the conjunctiva are congenital naevus, Dermoid and dermolipoma.

Congenital naevus:

- They typically are present at the epithelial – subepithelial junction. Compound naevus has got deeper stromal infiltration too having goblet cells histologically. They may be flat or elevated in appearance and brown or black in color. They normally are present close to limbus and shows trivial malignant changes. They are surgically excised only due to cosmetic concern.

Dermoid:

- They are congenital growth of bulbar conjunctive with a firm underlying attachment. Histologically they are composed collagen containing cystic swelling which is surfaced by derma or stratified squamous epithelium. Clinically they consist of smooth, yellowish conjunctival growth along side of limbus and included in choristomal tissue (normal tissue at abnormal place). They may be present in syndromic child as an associated feature. Surgical excision is warranted if they impede visual axis and for cosmetic reasons, reoccurrence is not frequent.

Dermolipoma:

- They are histologically close to Dermoid except of the fact that they also contain fatty elements. Clinically the growth is rather soft and mobile at limbus or outer canthus. Treatment is similar to Dermoid.

अलजी

सुश्रुतानुसार -

“जाता सन्धौ कृष्णशुक्लेऽलजी स्यात्तस्मिन्नेव ख्यापिता पूर्वलिङ्गैः। सु.उ. 2/9

यदि उपरोक्त वृत्त स्वरूप शोफ पतला न होकर स्थूल हो जाए → अलजी कहते हैं।

वाग्भट्टानुसार अलजी-

“कनीनस्यान्तरलजी शोफो रुकतोददाहवान्।” उ० 10/8

कनीनिक सन्धि में जो पीड़ा तथा दाह से युक्त शोथ होता है → अलजी।

विमर्श-

- 1) आचार्य सुश्रुत ने 'पर्वणी' का स्थान 'कृष्णशुक्ल'गत संधि माना है जबकि 'अष्टांगहृदयकार' वर्त्मशुक्लगत सन्धि में पर्वणी की उत्पत्ति मानते हैं।
- 2) आचार्य वाग्भट्ट ने एक 'अलजी' रोग का वर्णन पक्ष्मगत रोगों में भी किया है।

अलजी चिकित्सा प्रकरण -

सुश्रुतानुसार व वाग्भट्टानुसार असाध्य है।

Conjunctival intraepithelial neoplasia

- Conjunctival intraepithelial neoplasia includes different spectrum of pathologies including conjunctival dysplasia, carcinoma in situ and squamous cell carcinoma (SCC). First two conditions may be included in premalignant lesion where as SCC is a malignant tumor itself. When the abnormal cellular proliferation involves only partial thickness of the epithelium, it is classified as mild Conjunctival intraepithelial neoplasia, a condition also called dysplasia. When it affects full-thickness epithelium, it is classified as severe Conjunctival intraepithelial neoplasia, a condition also called carcinoma in situ.
- Squamous cell neoplasia can occur as a localized lesion confined to the surface epithelium (conjunctival intraepithelial neoplasia) or in a more invasive variance which has breach in the basement membrane and has invaded the underlying stromal tissue.. conjunctival intraepithelial neoplasia has a limited potential to metastasize, but SCC can spread to regional lymph nodes via the conjunctival lymphatics.
- Clinically, Conjunctival intraepithelial neoplasia appears as a soft, fleshy, sessile or minimally elevated lesion usually at the limbus on bulbar conjunctiva and infrequently seen in the fornicial or palpebral conjunctiva. This limbal growth may invade into various depths into the adjacent corneal.

- Mild Conjunctival intraepithelial neoplasia (dysplasia) form is characterized by a partial-thickness replacement of the normal epithelial cells by immature abnormal cells whereas severe Conjunctival intraepithelial neoplasia (carcinoma in situ) is characterized by a complete thickness replacement of the epithelium by carcinomatous cells.
- Invasive form of SCC occurs when the Conjunctival intraepithelial neoplasia infiltrate deep through the basement membrane into underlying stromal tissue. Clinically, invasive squamous cell carcinoma is generally greater in dimension and more raised than Conjunctival intraepithelial neoplasia.
- **Treatment:** localized lesion is surgically excised and the bare area is grafted with conjunctival or limbal transplantation. It is better to excise 2-3 mm more than the actual lesion for negative frozen sections. Residual disease is dealt with topical mitomycin C and 5fluorouracil. In advance orbital invasion an enucleation and even exenteration is required.

कृमिग्रन्थि

सुश्रुतानुसार/भा.प्र./यो.र.

“क्रिमिग्रन्थिर्वर्त्मनः पक्ष्मणश्च कण्डूं कुर्यः क्रिमयः सन्धिजाताः।

नानारूपा वर्त्मशुक्लस्य सन्धौ चरन्तोऽन्तर्नयनं दूषयन्ति।” सु.उ. 2/9

- वर्त्म तथा पक्ष्म की सन्धि में व अनेक प्रकार के कृमि कण्डू तथा छोटी-छोटी ग्रन्थियाँ उत्पन्न कर देते हैं उसे 'कृमिग्रन्थि' रोग कहते हैं।
 - तत्पश्चात् ये कृमि नेत्र के वर्त्म तथा शुक्लमण्डल की सन्धि का भक्षण करते हुए नेत्र के आभ्यान्तरिक भाग को भी दूषित कर देते हैं।
- डल्हन टीका** – “क्रिमीत्यादि। क्रिमीग्रन्थिवर्त्मशुक्लयोः सन्धौ भवति। तत्रैव नानारूपाः क्रिमयो वर्त्मनः पक्ष्मणश्च सन्धिं प्राप्ताः कण्डूं जनयति, अन्तश्चरन्तो भक्षयन्तो नयनं दूषयन्ति। असौ कफजः साध्यश्च।”

वाग्भट्टानुसार -

“अपांगे वा कनीनेवा कण्डूषापक्ष्मपोटवान्।

पूयासावी कृमिग्रन्थिर्ग्रन्थिः कृमियुतोऽर्तिमान्।।” अ.ह.उ. 10/8

- अपांग में अथवा कनीनिका में कण्डू तथा पक्ष्मपोट (शोथ) वाली एक ग्रन्थि की उत्पत्ति।
- भिन्न होने पर उसमें से पूयासाव होता है व कृमि उत्पत्ति हो जाती है।
- ग्रन्थि में पीड़ा होती है।

चिकित्सा प्रकरण

सुश्रुतानुसार-

“सम्यक् स्वित्ने कृमिग्रन्थौ भिन्नस्यात् प्रतिसारणम्।

त्रिफलातुत्थकासीससैन्धवैश्च रसक्रिया।।” सु.उ. 14/8

- इसी व्याधि में सम्यक् स्वेदन करने के पश्चात् शस्त्र से भेदन कर्म करना चाहिए।
- पूयादि को पूर्णतः निर्हरण कर अंजन द्रव्यों का प्रतिसारण करें।
- त्रिफला, नीलतुत्थ, कासीस व सैन्धव लवण इनकी यथाशास्त्र रसक्रिया करके वर्ति बनाकर → अंजन प्रयोग।

वाग्भट्टानुसार -

“कृमिग्रन्थिं करीषेण स्वित्नांभित्वाविलिख्य च।

त्रिफलाक्षौद्रकासीससैन्धवैः प्रतिसारयेत्।।” अ.ह.उ. 11/6

- गाय के सूखे गोबर द्वारा स्वेदन → ब्रीहिमुखशस्त्र से भेदन तथा लेखन।
- व्रण का त्रिफला, मधु, कासीस तथा सैन्धव लवण से प्रतिसारण कर तत्पश्चात् रोपण कर्म।

Blepharitis

Introduction:

- Blepharitis is chronic inflammation of the eyelid margin and commonly divided into chronic anterior and chronic posterior Blepharitis. Chronic anterior blepharitis again occurs in three different forms:
 1. Seborrhoeic Blepharitis
 2. Ulcerative Blepharitis
 3. Parasitic blepharitis

Seborrhoeic Blepharitis:

- This disease is represented by presence of white scales in the eyelashes root which falls off and replaced by newer flakes. These scales are associated with scalp dandruff. Flake removal leaves a hyperemic zone underneath but without ulceration.
- Clinical features: foreign body sensation of lids, matting of eyelashes, photophobia and burning which are more prominent in morning time. Loss of cilia (eyelashes) and change in shape of posterior lid margin.
- **Treatment:** local flakes/crusts are removed with sodium bicarbonate solution with application of antibiotic and steroidal cream (fusidic acid + beclomethasone) on lid margin. Scalp seborrhea is dealt with regular shampoo usage. Crusts may be removed with warm normal saline and balanced diet/proper nutrition will suffice.

Ulcerative/staphylococcal blepharitis:

- It is aggregation of hard, yellowish crusting around the base of eyelashes. Commonly responsible bacteria are Streptococcus, Staphylococcus and Propionibacterium acnes.
- **Clinical features:** mild itching, foreign body sensation, matting of the eyelashes and photophobia. Removal of these yellowish crusts leads to bleeding ulcers underneath. Ulcerative blepharitis may be associated with chronic conjunctivitis and the term 'blepharoconjunctivitis' is reserved for that. Watering and papillary conjunctivitis may be associated a clinical feature.
- **Complication:** trichiasis (misdirection of eyelashes), madarosis (loss of eyelashes), tylosis (thickening of the eyelid), epiphora, dry eye syndrome, ectropion and recurrent stye formation.

Chronic posterior blepharitis:

- Chronic posterior blepharitis is cause by chronic inflammation of Meibomian gland. Meibomian glands are present along the posterior margin of lid and are modified sebaceous gland. 20-30 Meibomian gland are present in each lid and open on the surface with isolated vertical tubal structures. Meibomian gland form like secretions is desiccated by bacterial lipase enzyme leading to chronic Meibomian at the lid margin.
- **Clinical features:** foreign body sensation of lids, matting of eyelashes, photophobia and burning which are more prominent in morning time. Telangectasia (capillary dilation) is readily seen on lid margin and tooth paste like secretions can be milked out the lid margin.
- **Management:** lid hygiene is particularly helpful apart from regular manual expression of the gland retained secretions. Rubbing of antibiotic and steroidal cream (fusidic acid + beclomethasone) on lid margin 2-3 times a day gives immediate relief. Hot compression and oral Doxycycline (100 mg X BD) for 4 weeks is an established treatment. Topical antibiotic eye drops are sometimes prescribed.

Parasitic blepharitis/Phthiriasis palpebrarum:

- This condition represents infestation of crab louse (phthirus pubis – commonly present in pubic hairs and may get transferred to other hair bearing areas like chest, axilla and eyelid) in the root of eyelashes. Crab louse or pubic louse is an insect that is an obligate ectoparasite in human beings. They feed exclusively on blood and human beings are the only known hosts of this parasite.
- Adult crab louse is about 1.2-2 mm long and has got an almost round body; hind legs are much larger than the front legs and have got large claws. Head louse (pediculus corporis) may sometime causes parasitic blepharitis.
- **Clinical features:** mild itching, foreign body sensation, lachrimation, matting of the eyelashes, conjunctivitis (rare) and mild photophobia.
- **Management:** manual lice removal with fine forceps and application of antibiotic and steroidal cream (fusidic acid + beclomethasone) on lid margin.